

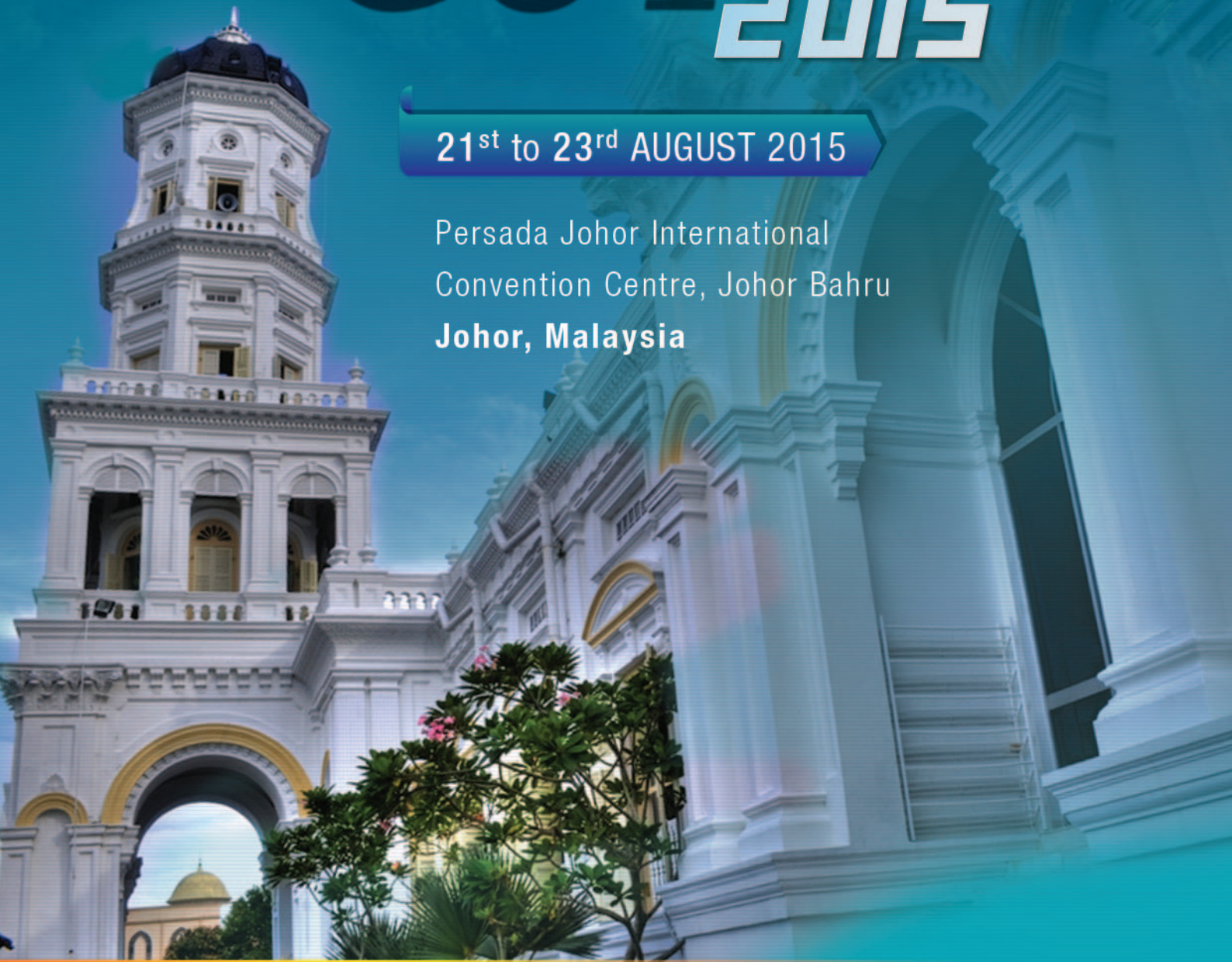

ANNUAL SCIENTIFIC CONGRESS OF THE
MALAYSIAN SOCIETY OF GASTROENTEROLOGY AND HEPATOLOGY

GUT 2015

21st to 23rd AUGUST 2015

Persada Johor International
Convention Centre, Johor Bahru
Johor, Malaysia



SOUVENIR PROGRAMME & ABSTRACT BOOK

CONTENTS

MSGH Committee 2013 - 2015	2
GUT 2015 - Organising Committee	
Message from the President, MSGH & Organising Chairperson, GUT 2015	3
15 th MSGH Distinguished Orator - Professor Dr Kentaro Sugano	4
12 th Panir Chelvam Memorial Lecturer - Professor Dr Yogesh Chawla	5
Programme At A Glance	6
Daily Programme	7 - 9
Moderators / Chairpersons	10
Faculty Bio-Data	11 - 15
MSGH Annual Scientific Meetings and Endoscopy Workshops	16 - 23
Annual Therapeutic Endoscopy Workshops - "Endoscopy"	(17 - 18)
Distinguished Endoscopy Lecturers	(18)
Annual Scientific Meetings - Overseas Invited Faculty	(19 - 22)
MSGH Oration Lecturers / Panir Chelvam Memorial Lecturers	(23)
Conference Information	24
Function Rooms & Trade Exhibition	25
Acknowledgements	26
Abstracts	27 - 90
Lectures & Symposia	(27 - 32)
Best Paper Award Presentations	(33 - 37)
Poster Presentations	(38 - 90)

MSGH COMMITTEE 2013 – 2015

<i>President</i>	Prof Dr Sanjiv Mahadeva
<i>President-Elect</i>	Dr Mohamed Akhtar Qureshi
<i>Immediate Past-President</i>	Dr Ramesh Gurunathan
<i>Hon Secretary</i>	Dr Tan Soek Siam
<i>Hon Treasurer</i>	Assoc Prof Dr Raja Affendi Raja Ali
<i>Committee Members</i>	Dr Chan Weng Kai Assoc Prof Dr Hamizah Razlan Datuk Dr Raman Muthukaruppan Dato' Dr Tan Huck Joo Dr Tee Hoi Poh Prof Dato' Dr Goh Khean Lee

ORGANISING COMMITTEE

<i>Organising Chairman</i>	Prof Dr Sanjiv Mahadeva
<i>Scientific Chairman</i>	Dato Dr Tan Huck Joo
<i>Scientific Co-Chairman</i>	Prof Dato' Dr Goh Khean Lee
<i>Committee Members</i>	Dr Mohamed Akhtar Qureshi Dr Chan Weng Kai Assoc Prof Dr Hamizah Razlan Assoc Prof Dr Raja Affendi Raja Ali Datuk Dr Raman Muthukaruppan Dr Ramesh Gurunathan Dr Tan Soek Siam Dr Tee Hoi Poh

MESSAGE FROM THE PRESIDENT, MALAYSIAN SOCIETY OF GASTROENTEROLOGY AND HEPATOLOGY & ORGANISING CHAIRPERSON, GUT 2015



It gives me great pleasure to welcome all delegates and our distinguished faculty to GUT 2015. The conference this year is being held for the first time in the bustling city of Johor Bahru, the southern most urban development in the Malaysian peninsular. Thanks to the commercial development of the Southern Economic Corridor in nearby Nusajaya, Johor Bahru has seen a rapid rate of development in recent years, including modern conference facilities for medical meetings like GUT 2015.

On behalf of the Malaysian Society of Gastroenterology and Hepatology (MSGH), I am proud to say that our Annual Scientific Meeting continues to deliver some of the highest standards of education in the South East Asian region, with GUT 2015 this year being no exception. The scientific programme chairman, Datuk Dr Tan Huck Joo, together with some able assistants from the committee, has once again, done a sterling job in putting together, a varied programme, covering a broad spectrum of gastroenterology and hepatology. We, in MSGH, have also worked hard to bring you leading experts from both Asia and the rest of the world, to update you with the latest developments in the field. GUT 2015 would not be possible without the assistance from our partners in the biomedical industry, and I would like to thank all of them, on behalf of MSGH, for their continued support.

Wishing you a fruitful and enjoyable time over the next 2.5 days in GUT 2015 - the ONLY major annual scientific congress in Gastroenterology and Hepatology in Malaysia.

A handwritten signature in black ink, consisting of stylized initials and a surname, likely 'SM Mahadeva'.

Professor Dr Sanjiv Mahadeva

15TH MSGH DISTINGUISHED ORATOR – PROFESSOR DR KENTARO SUGANO

Citation by Dr Mohamed Akhtar Qureshi



Dr Kentaro Sugano received his doctorate and degree in medicine at the University of Tokyo. Further education at the Tokyo University Hospital led to the PhD. Dr Sugano did research at the University of California and at the University of Michigan. His career continued at the University of Tokyo and the Jichi Medical School. Dr Sugano is Chief Professor and Chairman of the Department of Internal Medicine, Jichi Medical University and Deputy Director of Jichi Medical University Hospital. He is a Professor Emeritus at Jichi Medical University, since 2014.

Dr Sugano is a member of several national and international medical societies: Japanese Society of Internal Medicine (Council Member), Japanese Society of Gastroenterology (Member of the Board of Directors), Japanese Gastroenterological Endoscopy Society (Council Member), and Japanese Society for Helicobacter Research (Council Member), Japanese Gastric Cancer Association (Council Member), American Gastroenterology Association, Steering Committee Member of the International Gut Hormone Conference.

He served as the President of the Japanese Society of Gastroenterology (JSGE) from 2009 to 2014. At present, he is the President of the Organization of Japanese Digestive Disease Week (JDDW) which is the organisation of four major societies, JSGE, JSDE, JSH and JSDS, to hold the JDDW meeting in autumn, one of the largest academic meetings in Japan. In the Asian-Pacific region, he was nominated to be the President of the Asian-Pacific Association of Gastroenterology (APAGE), at the Bali meeting in 2014.

His major research interest is gastric cancer and *Helicobacter pylori*. In his department, Dr Hironori Yamamoto developed double-balloon enteroscopy, in collaboration with Fuji Film, which expands his research area to small intestinal diseases.

He has been serving as an Editorial Board Member in a number of international journals such as Gut, Digestive Diseases, Journal of Gastroenterology, Gastric Cancer, Regulatory Peptides, Digestion, Journal of Digestive Diseases and so on.

He has published more than 300 peer-reviewed articles in English, and wrote chapters in four monographs published in English. He is Co-Editor of “Gastric Cancer” and has been the Editor or Advisor to several other renowned international journals.

12TH PANIR CHELVAM MEMORIAL LECTURER – PROFESSOR DR YOGESH CHAWLA

Citation by Professor Dr Sanjiv Mahadeva



Professor Dr Yogesh Kumar Chawla graduated in medicine from the Netaji Subhash Chandra Bose Medical College, Jabalpur, India, in 1974, and very soon after, obtained his Master's Degree in Internal Medicine in 1978. Inspired by his mentors, he pursued his sub-specialisation in Gastroenterology in AIIMS, New Delhi, and joined the famous Postgraduate Institute of Medical Education & Research (PGIMER), Chandigarh, as a member of faculty in the Department of Hepatology in 1983. With his dedication to teaching and research, he quickly rose up the ranks, from Lecturer, to Asst, then Associate, followed by Additional and eventually, Professor in 1999. Along the way, he had also been appointed as the Head of the Department of Hepatology in 1995, a position he held until becoming the overall Director of PGIMER, in 2011. The latter is a position of immense responsibility, which he holds until today. The PGIMER in Chandigarh, is a 2000-bedded tertiary centre public institution which delivers state-of-the-art treatment, including organ transplantation and advanced cancer therapy. In addition, they are a major postgraduate training centre in the North of India, for various Medical and Allied-Health / Nursing disciplines.

It is no major surprise as to why Professor Chawla has risen to such high ranks in his institution. A prolific researcher, he has authored a total of 434 publications in both national and international peer-reviewed journals, including an additional 27 chapters in text books. He sits on the editorial board of numerous International Journals in the field of Hepatology. His main research has been in the areas of cirrhotic and non-cirrhotic portal hypertension, Budd-Chiari syndrome, viral hepatitis and biliary diseases. Professor Chawla is a member of numerous national, regional and international august medical organisations. He has been a steering member of Asian Consensus Working parties on cirrhotic and non-cirrhotic portal hypertension, acute on chronic liver failure and liver fibrosis.

His international recognition in the field of Hepatology earned him the Dr B C Roy Medical Council of India Silver Jubilee Research Award in 1999. This award is presented by the President of India on an annual basis to eminent medical persons who have made a significant contribution to the country. In 2015, he was honoured by the Government of India with "Padma Shri", the 4th highest Indian civilian award, in recognition of his work once again. "Padma" means "Lotus" in the ancient Indian language of Sanskrit, and "Shri" is a noble term for either a gentleman or a lady.

He is a much sought-after Speaker in both Asian and Western Scientific Conferences, and has lectured widely over the years. It is indeed a great honour & privilege for the Malaysian Society of Gastroenterology and Hepatology to have Professor Dr Yogesh Chawla deliver the Panir Chelvam Memorial Lecture at GUT 2015.

PROGRAMME AT A GLANCE

Date Time	21 st August 2015 (Friday)	22 nd August 2015 (Saturday)	23 rd August 2015 (Sunday)
0730 – 0820	Registration	Meet-the-Expert Breakfast Sessions (1 – 3)	Meet-the-Expert Breakfast Sessions (4 & 5)
0830 – 0950	Symposium 1 GI Bleed	Case Discussion	Symposium 6 FGID
0950 – 1030	Lecture 1 15 th MSGH Oration	Lecture 3 12 th Panir Chelvam Memorial Lecture	Lecture 4
1030 – 1100	TEA		
1100 – 1220	Best Paper Award Presentations	Symposium 3 Microbiota	Case Discussion
1220 – 1330	Lunch Satellite Symposium [AstraZeneca]	Lunch Satellite Symposium [Takeda]	LUNCH
1400 – 1430	Friday Prayers	Symposium 4 IBD	
1430 – 1540	Symposium 2 Colorectal		
1540 – 1630	(1550 – 1630) Lecture 2	Symposium 5 Portal Hypertension	
1630 – 1700	Tea Satellite Symposium [Reckitt Benckiser]		
1700 – 1800		Tea Satellite Symposium [Abbvie]	
1800 – 1930		MSGH Annual General Meeting	
2000 – 2200	Faculty Dinner (by invitation only)		

Daily Programme
21ST AUGUST 2015, FRIDAY

- 0730 – 0820 Registration
- 0830 – 0950 **SYMPOSIUM 1 GI Bleed** > Convention Hall 301
Chairpersons: Andrew Gunn Kean Beng, Yoong Kar Yaw
- Preventing PUD related bleeding
Francis Chan
 - The bleeding colon: Colonoscopy, angiography or surgery?
Lim Jit Fong
 - The role of radiology in GI bleed
Teik-Choon See
- 0950 – 1030 **LECTURE 1** > Convention Hall 301
Chairperson: Jayaraman Menon
- 15th MSGH Oration**
Helicobacter pylori and gastric cancer - A balanced view [pg 27]
Kentaro Sugano
Citation by Dr Mohamed Akhtar Qureshi
- 1030 – 1100 TEA
- 1100 – 1220 **Best Paper Award Presentations**
Chairpersons: Tan Huck Joo, Mohamed Akhtar Qureshi
- 1220 – 1430 **Lunch Satellite Symposium [AstraZeneca]** > Convention Hall 301
Chairperson: Tan Huck Joo
 High cardiovascular risk patients: Challenges in management of upper GI bleed
Francis Chan
 Friday Prayers
- 1430 – 1540 **SYMPOSIUM 2 Colorectal** > Convention Hall 301
Chairperson: Wan Khamizar
- Colorectal cancer screening - The challenges and pitfalls [pg 27]
Yeoh Khay Guan
 - Colonic adenoma surveillance [pg 28]
Leung Wai Keung
 - Colonic polyp with high grade dysplasia: Endoscopic or surgical treatment?
Lim Jit Fong
- 1550 – 1630 **LECTURE 2** > Convention Hall 301
Chairperson: Tan Soek Siam
 Management of HCV related cirrhosis [pg 28]
Rajender Reddy
- 1630 – 1700 **Tea Satellite Symposium [Reckitt Benckiser]** > Convention Hall 301
Chairperson: Goh Khean Lee
- 1 PPI Refractory GERD - Definition and size of the problem
Goh Khean Lee
 - 2 Defining acid pocket and other novel mechanisms in the pathogenesis of GERD
Lee Yeong Yeh
 - 3 When reflux symptoms persist despite PPI: What should we do?
Goh Khean Lee
- 2000 – 2200 **Faculty Dinner (by invitation only)** > Tosca Restaurant, Double Tree Hilton, JB

Daily Programme
22ND AUGUST 2015, SATURDAY

- 0730 – 0820 **Meet-the-Expert Breakfast Sessions** (Concurrent)
1. Liver cancer - When to refer to a surgeon? > Tanjung Puteri 304-305
K K Madhavan
Moderator: Yoong Boon Koon
 2. AGA guideline on treatment and prevention of HBV reactivation during immunosuppressive therapy > Tanjung Puteri 306
Rajender Reddy
Moderator: Maylene Kok
 3. Obscure GI bleed after negative endocapsule - What is next? > Suite 302
Leung Wai Keung
Moderator: Chan Weng Kai
- 0830 – 0950 **Case Discussion**
Moderator: Yoong Boon Koon
 Liver nodules [pg 29]
Convenor: Razman Jarmin
Panel: Yogesh Chawla, Teik-Choon See, K K Madhavan, Rajender Reddy
- 0950 – 1030 **LECTURE 3** > Convention Hall 301
Chairperson: Ramesh Gurunathan
12th Panir Chelvam Memorial Lecture
 Non cirrhotic portal hypertension
Yogesh Chawla
Citation by Professor Dr Sanjiv Mahadeva
- 1030 – 1100 TEA
- 1100 – 1220 **SYMPOSIUM 3 Microbiota** > Convention Hall 301
Chairperson: Amry A Rahim
- The GUT microbiota in irritable bowel syndrome: Friend or foe [pg 29]
Uday Ghoshal
 - Modulating the GUT microbiota in IBD - Does it work? [pg 30]
Simon Travis
 - Current techniques for evaluating the GUT microbiome [pg 30]
Ujjala Ghoshal
- 1220 – 1310 **Lunch Satellite Symposium** [Takeda] > Convention Hall 301
Chairperson: Tan Huck Joo
 Guidelines for the management of refractory GERD
Lawrence Ho Khek Yu
- 1400 – 1520 **SYMPOSIUM 4 IBD** > Convention Hall 301
Chairpersons: Ida Normiha Hilmi, Mohamad Ismail B Ali, Raja Afendi Raja Ali
- Mucosal healing as the new target in IBD management - How far and how deep should we go? [pg 31]
Simon Travis
 - Optimising the quality of care for the IBD patient in evolving economies [pg 31]
Leung Wai Keung
 - Management of anal fistulae in IBD
Mohamed Akhtar Qureshi
- 1520 – 1540 **Case Studies**
 IBD in pregnancy, moderate refractory UC
Panel: Simon Travis, Leung Wai Keung

Daily Programme
22ND AUGUST 2015, SATURDAY

- 1540 – 1700 **SYMPOSIUM 5 Portal Hypertension** > Convention Hall 301
Chairpersons: Raman Muthukaruppan, Ahmad Shukri Md Salleh
- The role of transient elastography in portal hypertension
Yogesh Chawla
 - TIPSS in portal hypertension
Teik-Choon See
 - The role of surgical treatment in portal hypertension
K K Madhavan
- 1700 – 1800 **Tea Satellite Symposium [Abbvie]** > Convention Hall 301
Chairperson: Goh Khean Lee
 HCV - Past, present and future [pg 32]
Rajender Reddy
- 1800 – 1930 **MSGH Annual General Meeting**

Daily Programme
23RD AUGUST 2015, SUNDAY

- 0730 – 0820 **Meet-the-Expert Breakfast Sessions (Concurrent)** > Tanjung Puteri 304-305
4. HBV therapy - Choices of drugs and outcomes
Lim Seng Gee
Moderator: Chan Wah Kheong
 5. Practical use of esophageal manometry > Tanjung Puteri 306
Rajesh Sainani
Moderator: Ngiu Chai Soon
- 0830 – 0950 **SYMPOSIUM 6 FGID** > Convention Hall 301
Chairpersons: Tee Hoi Poh, Rosemi Bin Salleh
- Esophageal motility disorder - When to refer [pg 32]
Rajesh Sainani
 - Should Asian IBS patients be routinely assessed for SIBO and lactose intolerance
Uday Ghoshal
 - NCCP
Lawrence Ho Khek Yu
- 0950 – 1030 **LECTURE 4** > Convention Hall 301
Chairpersons: Hamizah Razlan, Ho Shiaw Hooi
 HBV update from the Singapore Hepatitis Conference
Lim Seng Gee
- 1030 – 1150 **Case Discussion**
Chairperson: Ngiu Chai Soon
 Upper GI Disorder
Convenor: Lee Yeong Yeh
Panel: Rajesh Sainani, Uday Ghoshal, Lawrence Ho Khek Yu
- 1150 – 1300 **LUNCH**

MODERATORS / CHAIRPERSONS

Ahmad Shukri Md Salleh

Hospital Sultanah Nur Zahirah
Kuala Terengganu, Terengganu

Amry A Rahim

Hospital Universiti Sains Malaysia
Kubang Kerian, Kelantan

Andrew Gunn Kean Beng

Hospital Sultanah Aminah
Johor Bahru, Johor

Chan Wah Kheong

University of Malaya, Kuala Lumpur

Chan Weng Kai

Hospital Sultanah Aminah, Johor Bahru, Johor

Goh Khean Lee

University Malaya Medical Centre, Kuala Lumpur

Ramesh Gurunathan

Sunway Medical Centre, Petaling Jaya, Selangor

Hamizah Razlan

Universiti Kebangsaan Malaysia Medical Centre
Kuala Lumpur

Ho Shiaw Hooi

University Malaya Medical Centre, Kuala Lumpur

Ida Normiha Binti Hilmi

University Malaya Medical Centre, Kuala Lumpur

Maylene Kok

Sarawak General Hospital, Kuching, Sarawak

Jayaraman Menon

Hospital Queen Elizabeth, Kota Kinabalu, Sabah

Mohamad Ismail B Ali

Johor Specialist Hospital, Johor Bahru, Johor

Mohamed Akhtar Qureshi

Sunway Medical Centre, Petaling Jaya, Selangor

Raman Muthukaruppan

Hospital Queen Elizabeth, Kota Kinabalu, Sabah

Ngiu Chai Soon

Department of Medicine
Universiti Kebangsaan Malaysia Medical Centre
Kuala Lumpur

Raja Affendi Raja Ali

Universiti Kebangsaan Malaysia Medical Centre
Kuala Lumpur

Rosemi Bin Salleh

Hospital Raja Perempuan Zainab II, Kota Bharu
Kelantan

Tan Huck Joo

Sunway Medical Centre, Petaling Jaya, Selangor

Tan Soek Siam

Hospital Selayang, Batu Caves, Selangor

Tee Hoi Poh

Hospital Tengku Ampuan Afzan, Kuantan, Pahang

Wan Khamizar

Hospital Sultanah Bahiyah, Alor Setar, Kedah

Yoong Boon Koon

University Malaya Medical Centre, Kuala Lumpur

Yoong Kar Yaw

Hospital Sultan Ismail, Johor Bahru, Johor

FACULTY BIO-DATA

**FRANCIS CHAN KA-LEUNG**

Professor Dr Francis Chan Ka-Leung is Professor of Medicine and Therapeutics and Dean of the Faculty of Medicine at the Chinese University of Hong Kong (CUHK) in Hong Kong. Professor Chan received his Bachelor of Medicine and Bachelor of Surgery (MBChB) degree from CUHK. After completing his internal medicine residency and his gastroenterology fellowship at the Prince of Wales Hospital in Hong Kong, and then at the Foothills Hospital in Alberta, Canada, he joined the Division of Gastroenterology & Hepatology at CUHK, where he went on to receive his Doctor of Medicine degree and assume his current roles. Professor Chan was appointed Specialty Board Chairman of Gastroenterology and Hepatology in Hong Kong in 2010, and received the prestigious Doctor of Science degree in 2011 from CUHK in recognition of his outstanding academic achievements.

Professor Chan has authored or co-authored more than 400 scientific articles, and was the first academic to publish seven first-authored original articles in the *New England Journal of Medicine* and *The Lancet*. His research work has revolutionised management guidelines worldwide, including those issued by the American College of Gastroenterology, the American Heart Association, and many European countries (Maastricht IV Consensus 2012). Further to his clinical duties, Professor Chan has made significant contributions to public health in Hong Kong. He launched the first bowel cancer screening programme in the eastern New Territories in 1999 and organised a large-scale SARS screening test for over 12,000 people during the SARS outbreak in 2003. Among his many awards and honours, Professor Chan was appointed “Justice of the Peace” by the Hong Kong Government in 2010.

**YOGESH CHAWLA**

Professor Dr Yogesh Chawla is Professor & Head of the Department of Hepatology, Postgraduate Institute of Medical Education and Research, Chandigarh. Dr Chawla graduated from Jabalpur Medical School and received his postgraduate training in Internal Medicine from the same University. He then trained in Gastroenterology at AIIMS, New Delhi, and joined PGIMER, Chandigarh after completing his training. He is an active member of several International and National medical organisations, including Fellow of American College of Gastroenterology (FACG), European Association for the Study of the Liver (EASL), National Academy of Medical Sciences (NAMS), Indian Association for Study of the Liver (INASL), Indian Society of Gastroenterology (ISG), Society of Gastrointestinal Endoscopy of India (SGEI), Indian Medical Association (IMA). Dr Chawla is the recipient of many International and National awards and honours, including the prestigious Dr B C Roy Medical Council of India Silver Jubilee Research Award in 1999, M N Sen Oration Award by Indian Council of Medical Research (ICMR) in 1997, Amrut Mody Unichem Prize from ICMR in 1999, Olympus Mitra Endoscopy Award by Indian Society of Gastroenterology in 1999, Parke Davis Oration Award by Indian Society of Gastroenterology in 2002.

Dr Chawla is the author of more than 240 publications, including original papers, reviews, book chapters and a monograph. His main research work has been in the areas of cirrhotic and noncirrhotic portal hypertension, Budd-Chiari syndrome, viral hepatitis and biliary diseases.

**UDAY GHOSHAL**

Professor Dr Uday C Ghoshal is currently working as Additional Professor in the Department of Gastroenterology at SGPGI, Lucknow. He is also the Faculty incharge of Gastrointestinal Pathophysiology and Motility Laboratory in the same Department. In spite of being a busy clinician and endoscopist, he has published 132 papers, 19 book chapters and edited two books. He is a Fellow of American College of Gastroenterology, a member of American Gastroenterology Association, American Motility Society, Indian Society of Gastroenterology (Governing Council Member twice, 2003-2006 and 2008-2011), Indian National Association of Study of Liver (Governing Council Member from 2008-2011), Society of Gastrointestinal Endoscopy of India, Association of Physicians of India and National Academy of Sciences. He is a Founder Member and the Secretary General of Asian Neurogastroenterology and Motility Association and President of Uttar Pradesh Chapter of Indian Society of Gastroenterology. He is Member of Editorial Board of *J Gastroenterol Hepatol*, *Indian J Gastroenterol* (Associate Editor of Luminal Gastroenterology section, since January 2010), *J Med Sci Res*, *Gastrointestinal Cancer Review Letter*, *World J Gastroenterol* and Associate Editor of *J Neurogastroenterology and Motility* and *International Journal of Cancer Research* and peer reviewer to twenty seven international journals. He is the National Coordinator of Indian Society of Gastroenterology Task Force on irritable bowel syndrome. He is also the Chair of Epidemiology and Infection section of Asian IBS Consensus Team and Asian Dyspepsia Consensus Team. He is a Member of Asian Barretts Consortium. He was a visiting clinician to Mayo Clinic, Scottsdale, USA, Hamad Medical Corporation, Doha, Qatar, and WHO Fellow in Prince of Songkhla Univeristy, Hat Yai, Thailand. He is highly skilled in various diagnostic and therapeutic endoscopy including ERCP, capsule endoscopy, GI manometry and breath tests. He is involved in patient education through SPREAD (www.spread.net.in). Luminal gastrointestinal diseases and GI motility is the major area of his interest. He is a passionate researcher and teacher not only in Gastroenterology, but also in research methodology and Biostatistics.

FACULTY BIO-DATA (CONT'D)

**UJJALA GHOSHAL**

Professor Dr Ujjala Ghoshal is presently Additional Professor in Microbiology & Faculty incharge of Parasitology Section of the Department of Microbiology, Sanjay Gandhi Postgraduate Institute of Medical Sciences, Lucknow. She is Executive Council Member of "Indian Academy of Tropical Parasitology", Jt Secretary of Indian Association of Medical Microbiologist, UP Chapter and Founder Member and general Secretary of UP & UK Chapter of Indian Academy of Tropical Parasitology. Her research interest includes Parasitology and GI microbiology. She has authored more than 60 publications in peer-reviewed journals, four book Chapters, Editorial and review articles.

Professor Ghoshal has received more than 23 awards, including Presidential award at Asian Pacific Digestive Disease week 2006, Nov 26th-29th in Cebu City, Philippines, and Indian Association of Medical Microbiologists Silver Jubilee Award for Best Paper in 2012. She has Received "WHO-Fellowship" on communicable disease control in Ministry of Public Health, Department of Communicable disease, Thailand, in June 2009.

**GOH KHEAN LEE**

Khean-Lee Goh is Professor of Medicine and Head of the Gastroenterology Unit, Department of Medicine at the University of Malaya, Kuala Lumpur, Malaysia. A leading figure in academic Gastroenterology in Malaysia, he has published over 200 peer-reviewed publications, has held Editorial Board positions in numerous journals, including Editor Emeritus of Journal of Gastroenterology and Hepatology. He has been a leading expert in numerous Asia-Pacific Consensus and Guideline publications. Passionate about endoscopy, Prof Goh has been instrumental in internationally-acclaimed live Endoscopy Workshops in Malaysia, with his Unit earning the OMED World Organization of Digestive Endoscopy Centre of Excellence Award in 2008. He is currently the President of the Asia Pacific Association of Gastroenterology and Vice-President of the World Gastroenterology Organisation. He was awarded the Merdeka Award in 2011, a national recognition of his outstanding academic achievements in the field of medicine in Malaysia.

**LAWRENCE HO KHEK YU**

Professor Dr Lawrence Ho is Group Director (Research), National University Health System, Vice-Dean (Research), School of Medicine, National University of Singapore, and a Senior Consultant, Division of Gastroenterology & Hepatology, Department of Medicine, National University Hospital, Singapore.

Professor Lawrence Ho graduated with first class honours from the University of Sydney, and undertook his training in therapeutic gastrointestinal endoscopy and endoscopic ultrasound at the Brigham and Women's Hospital, and Hospital of the University of Pennsylvania, USA. He has been invited to perform live case demonstrations in numerous international endoscopy workshops. He chairs the Asian Endoscopic Ultrasound Group, which is a platform for leading EUS experts to promote endoscopic ultrasound training and professional development of endosonographers in the Asian region.

He was President of Gastroenterological Society of Singapore in 2005-2006. He is the current Chair of the Asian Barrett's Consortium. In collaboration with Genomic Institute of Singapore, the team has made important strides in the cloning of oesophageal stem cells from patients with Barrett's oesophagus. He has published >160 peer-reviewed papers, > 10 book chapters, co-edited two books, and held eight patents in translational products. In recognition of his achievement in clinical & translational research, he was awarded the Inaugural National University Health System Leadership Award - Clinical Innovator (Individual) Award in 2011. As co-inventor for the ground-breaking technology of the Master and Slave Transluminal Endoscopic Robot (MASTER), he was part of the team who developed the world's first flexible robotic endoscopy system, which was successfully used to perform endoscopic submucosal dissection in human patients. Both the inventors co-founded a start-up company, Endomaster Pte Ltd and received the President's Technology Award, the highest honour bestowed on exceptional research scientists and engineers in Singapore for their excellent achievements in science and technology, in 2012. Working with the Department of Bioengineering, NUS, the team pioneers the world's one-of-a-kind In-Vivo Molecular Diagnostic System, which can make realtime diagnosis of GI cancer simpler. He co-founded the second start-up company, Endofotonics Pte Ltd to develop this product.

He chairs the Gastroenterology Residency Advisory Committee, and sits in the Joint Commission on Specialist Training, Ministry of Health. He is a Member, Specialist Accreditation Board, Ministry of Health. He just stepped down as Chair, University Medicine Cluster, and Head, Department of Medicine, National University Healthcare System, following six illustrious years of leadership where he was instrumental in enhancing the academic culture, and growing the next generation of academic leaders within the university department.

FACULTY BIO-DATA (CONT'D)

LEUNG WAI KEUNG

Professor Dr Wai-Keung Leung is currently a Clinical Professor at the Department of Medicine of the University of Hong Kong, and the Deputy-Director of the Intergrated Endoscopy Centre, Queen Mary Hospital, Hong Kong. Professor Leung graduated from the Faculty of Medicine of the Chinese University of Hong Kong in 1991, and completed his residency and fellowship at the Prince of Wales Hospital of Hong Kong. He then furthered his training overseas at the Division of Gastroenterology, Baylor College of Medicine, USA. After returning from overseas training, he has been working as a Faculty in the Department of Medicine and Therapeutics of the CUHK for eight years. Before assuming his current position at the CUHK, he was the Head of Department of Medicine of the Union Hospital of Hong Kong.

Professor Leung has contributed more than 200 original articles and book chapters to the international scientific and medical communities. He has a wide research interest in gastroenterology and endoscopy including HP, gastric carcinogenesis, IBD, capsule endoscopy, screening colonoscopy and epigenetic changes in gastrointestinal cancer. In recognition of his contributions to research excellence, he has won prizes and awards from World Congress of Gastroenterology, APDW, and the European HP Study Group. Prof Leung has delivered more than 80 lectures in local and international meetings. He also serves in the Editorial Board of *Helicobacter*, *Hepatogastroenterology* and *World Journal of Gastroenterology*. He is also President of the Hong Kong IBD Society.

LIM SENG GEE

Professor Dr Lim Seng Gee is Professor, Department of Medicine, National University of Singapore, Director and Senior Consultant of Hepatology services, Division of Gastroenterology and Hepatology, NUH, Expert Panel Member, Centre for Drug Administration (CPA) and Centre for Drug Evaluation (CDE), Ministry of Health, Singapore, Chairman, Singapore Hepatitis Conference (annual), inaugural conference 2014.

Prof Lim attained his basic medical degree with honours (MBBS Hons) from the University of Monash, Melbourne, Australia. He later pursued a doctorate degree (MD) in Monash, and was awarded the FRACP (Australia), FRCP (London), FAMS (Gastroenterology, Singapore). His main clinical work focuses on the treatment of viral hepatitis (especially B and C), liver disease and liver cancer. Prof Lim's research activities include leadership in Hepatology research, which focuses on improving treatment for chronic hepatitis B and C, pathophysiology of hepatitis B disease, HBV virology, immunological mechanisms of HBeAg seroconversion, and loss of immune tolerance to hepatitis B virus. He also has an interest in pathophysiology and treatment of liver cancer, primary hepatocyte culture, hepatocyte function, drug related liver disease and non-alcoholic fatty liver disease. Prof Lim has over 100 publications in peer-reviewed journals and sits on the Editorial Board of *Liver International* and *GastroHep.com*. He has received over S\$5 million in research grants and is a reviewer for Singapore's grant funding agencies and the American Association for Liver Disease Annual Meeting. Prof Lim has been an invited speaker at AASLD, EASL and APASL in 2013 and 2014, and is a regular speaker at numerous International and Regional meetings on liver disease and viral hepatitis.

K K MADHAVAN

Professor Dr Krishnakumar Madhavan is Professor and Head, Department of Surgery, National University of Singapore, Director of Singapore National Liver Transplant Programme and Co-Director, National University Centre for Organ Transplantation, NUHS.

After initial schooling and undergraduate medical education in India, Professor Madhavan did his MS in General Surgery at the Post-Graduate Institute of Medical Education & Research. After doing the FRCS from the Royal College of Surgeons of Edinburgh, he went for further Higher Surgical Training in the United Kingdom, and after successfully completing this training, was appointed in 1996, a Consultant General and Transplant Surgeon at the Royal Infirmary of Edinburgh. After 11 years in that post, he has come to Singapore to join the NUS/NUH. In addition to all aspects of liver transplantation, he has extensive experience in kidney and pancreatic transplantation and also the whole spectrum of benign and malignant hepatobiliary and pancreatic surgery. He was also deeply involved in surgical training over the years and till recently, was the Deputy Chair of the surgical training committee for the South East of Scotland, and tutor and convener for the Basic surgical skills course of the RCSEd. He has also been an examiner for the FRCS, AFRCS and MRCS examinations and recently, has joined the panel of examiners for the exit FRCS examination (intercollegiate). His current research interests include the role of chemoembolisation in the management of hepatocellular carcinoma, management of cholangiocarcinoma, role of portocaval shunting in Piggy-back liver transplants, various aspects of live donor liver transplantation and saphenovenous peritoneal shunting in intractable ascites due to cirrhosis of liver. He is a co-author of many papers pertaining to his field of interest.

FACULTY BIO-DATA (CONT'D)

**RAJENDER REDDY**

Professor Dr K Rajender Reddy is the Ruimy Family President's Distinguished Professor of Medicine, and Professor of Medicine in Surgery in the Division of Gastroenterology/Hepatology at the University of Pennsylvania in Philadelphia, Pennsylvania. He is the Director of Hepatology, Medical Director of Liver Transplantation, and the Director of the Viral Hepatitis Center.

Professor Reddy received his medical education from Osmania Medical College in Hyderabad, India. He then completed a residency in internal medicine at New York Medical College Hospitals, a Fellowship in Gastroenterology at East Tennessee State University College of Medicine, and a Fellowship in Hepatology at the University of Miami School of Medicine. Subsequently, he joined the faculty at the University of Miami, and in October 2001, Dr Reddy moved to the University of Pennsylvania to the current position.

A Fellow of the American College of Physicians, American College of Gastroenterology, and the Royal College of Physicians (UK), Dr Reddy is also a Fellow and Councilor-at-Large of the American Association for the Study of Liver Diseases. He has held several Visiting Professorships at Medical Schools throughout the World. He has trained several fellows and mentored numerous research assistants throughout his career.

Professor Reddy has authored or co-authored over 350 peer-reviewed papers on a spectrum of hepatobiliary topics that include liver transplantation, chronic C viral hepatitis, HIV and the liver, and hepatocellular carcinoma. In addition, he has edited and contributed to several text books, and has participated in numerous scientific presentations at National and International meetings. He serves on the Editorial Boards of prestigious journals such as Liver Transplantation, Hepatology, Liver International, and is an ad-hoc reviewer for several journals.

Professor Reddy also has participated in a number of clinical trials that have advanced the understanding of the therapy of chronic viral hepatitis. He has been the recipient of both federal and non-federal funding for clinical research. His current research interests include areas of liver transplantation, viral hepatitis, and hepatocellular carcinoma.

**RAJESH SAINANI**

Dr Rajesh Sainani is a gastroenterologist at Jaslok & HN Reliance Foundation Hospitals in Mumbai, India. He has done his fellowship in gastrointestinal motility from Royal Melbourne Hospital, Australia. He is in-charge of the gastrointestinal physiology & motility laboratory and runs a pelvic floor clinic. His interests are in reflux, constipation and gastrointestinal motility disorders.

**TEIK-CHOON SEE**

Dr Teik-Choon See is a Consultant Interventional Radiologist at Cambridge University Hospitals (CUH) NHS Foundation Trust, since 2005. He qualified from the University College Dublin and subsequently, underwent surgical training (FRCS) and later, radiology training (FRCR) in Cambridge and London. He performs a wide range of vascular and non-vascular interventional procedures with a special interest in Interventional Oncology and Hepato-biliary Intervention including TAE, TACE, SIRT, RFA, TIPSS, Portal vein embolisation, and biliary drainage/stenting. He is a Co-Investigator in liver and vascular related research. He chairs the East of England Interventional Radiology Group. Currently, he is the Clinical Director in Imaging at CUH. He is a Member of the Scientific Programme Committee at the Royal College of Radiologists (RCR), Elected Member of the Safety & Quality Subcommittee, as well as in-coming Chair of the Audits & Registries Subcommittee of the British Society of Interventional Radiology. He also has an interest in education and is a Senior Examiner of the RCR and Course Director of the Cambridge FRCR Course.

FACULTY BIO-DATA (CONT'D)

**KENTARO SUGANO**

Professor Dr Kentaro Sugano is Chief Professor and Chairman of the Department of Internal Medicine, Jichi Medical University and Deputy-Director of Jichi Medical University Hospital. Dr Sugano received his Medical and doctorate degree at the University of Tokyo. He then went on to receive his PhD at the Tokyo University Hospital. Dr Sugano underwent his further training in USA, at the University of California, and University of Michigan. His further career continued at the University of Tokyo and the Jichi Medical School.

Dr Sugano is currently the President of the Asia Pacific Association of Gastroenterology. He is a Member of several national and international medical societies: Japanese Society of Internal Medicine (Council Member), Japanese Society of Gastroenterology (Member of the Board of Directors), Japanese Gastroenterological Endoscopy Society (Council Member), and Japanese Society for Helicobacter Research (Council Member), Japanese Gastric Cancer Association (Council Member), American Gastroenterology Association, Steering Committee Member of the International Gut Hormone Conference. He is Co-Editor of "Gastric Cancer" and has been the Editor and Advisor to many other renowned international journals. He has authored/co-authored more than 300 research publications in the field of internal medicine.

**SIMON TRAVIS**

Professor Dr Simon Travis is Group Head and Consultant Physician/Gastroenterologist at the John Radcliffe Hospital, Oxford, and a Fellow of Linacre College at the University of Oxford. Prof Travis qualified from St Thomas' Hospital, London, and trained in Gastroenterology in London and Oxford, where he did his PhD on colonic epithelial electropysiology. He was previously Chair of the IBD Section of the British Society of Gastroenterology, Council Member of BSG, Chair of the Scientific Committee of ECCO. He is President of the European Crohn's and Colitis Organisation (ECCO). He is Editorial Board Member of Gut and Journal of Crohn's and Colitis, among other journals. His research interests focus on inflammatory bowel disease clinical prediction and outcomes in clinical trials. Prof Travis is the author of six books, 27 chapters and over 130 papers. He is author of 11 peer-reviewed international guidelines, including the ECCO Consensus Guidelines on Crohn's disease (2006, 2010) and ulcerative colitis (2008, 2011).

**YEOH KHAY GUAN**

Professor Dr Yeoh Khay Guan is concurrently Deputy Chief Executive (Academic Enterprise), National University Health System and Dean of the Yong Loo Lin School of Medicine, National University of Singapore. He practises as a Senior Consultant at the Division of Gastroenterology and Hepatology, National University Hospital (NUH).

Dr Yeoh's research interest is in enhancing the early detection of gastric and colorectal cancers. He is the Lead Principal Investigator of the Singapore Gastric Cancer Consortium, a national flagship research group, which aims to improve the outcomes for gastric cancer by early detection, improving treatment and advancing the understanding of gastric carcinogenesis. He has published over 135 peer-reviewed papers in international journals. He also chairs the National Colorectal Cancer Screening Committee of the Health Promotion Board, Ministry of Health, which recommends guidelines for the national colorectal screening programme in Singapore.

Dr Yeoh received his MBBS (Bachelor of Medicine, Bachelor of Surgery) from NUS in 1987. He trained in internal medicine and gastroenterology at NUH. He is a Fellow of the Academy of Medicine, Singapore, Fellow of the Royal College of Physicians of London and Glasgow, and a Member of the American Gastroenterology Association and American Society of Gastrointestinal Endoscopy. He also serves as a reviewer for several journals and grant funding agencies. He has received several international awards for his research work, including the Nishi-Takahashi Lectureship at the 9th International Gastric Cancer Conference in 2011, and the Emerging Leader Lectureship award by the Journal of Gastroenterology & Hepatology Foundation, in 2006.

FACULTY BIO-DATA

**MOHAMED AKHTAR QURESHI**

Dr Qureshi graduated with honours from the Royal College of Surgeons in Ireland, in 1987. He was subsequently trained in Ireland, and England completing his basic, higher and advanced surgical training. Dr Qureshi returned to Malaysia in 1996, to join the Universiti Kebangsaan Malaysia where he headed the colorectal unit, training local postgraduates. He subsequently moved to the International Medical University as Professor and Head of Surgery in 1999, where he set up the surgical syllabus for IMU. Dr Qureshi was the Chairman of the National Committee on colorectal cancer screening guideline census. He is a Founding Member and Past President of the Malaysian Society of Colorectal Surgeons, and has been instrumental in developing colorectal surgery as a sub-specialty in Malaysia.

Dr Qureshi has also served as a Council Member of the College of Surgeons of Malaysia, and the ASEAN Colorectal Society. Currently, Dr Qureshi is the President-Elect of the Malaysian Society of Gastroenterology and Hepatology. Dr Qureshi has served as a reviewer of several medical journals, including *The Surgeon*, *Journal of Gastroenterology & Hepatology*, *Medical Journal of Malaysia*, and *Hospital Practice Seremban*.

Dr Qureshi is an Examiner for the FRCS exams, as well as an External Examiner for several local public and private universities. He has had an interest in both clinical surgery and research, with over 100 scientific publications on surgical issues, in both local and international journals, book chapters and abstracts. He has been an invited speaker and surgeon for live workshops at numerous local, regional and international meetings. Dr Qureshi has been called as an expert to advice on medico-legal cases in Malaysia and Singapore, for over 15 years.

**LIM JIT FONG**

Dr Lim is a general and colorectal surgeon specialising in anorectal ultrasound, anorectal physiology and pelvic floor disorders. He has special interest in management of anal fistula, haemorrhoids and laparoscopic colorectal surgery. Dr Lim currently serves on the Executive Committee of the Society of Colorectal Surgeons, Singapore (SCRS), Society for Continence of Singapore (SFCS), and Chapter of General Surgery in the Academy of Medicine, Singapore. Dr Lim runs his private practice at Gleneagles Medical Centre, Singapore.

**MSGH
ANNUAL SCIENTIFIC
MEETINGS**

AND

ENDOSCOPY WORKSHOPS

THE PROUD TRADITION OF THE
MALAYSIAN SOCIETY OF
GASTROENTEROLOGY AND HEPATOLOGY

ANNUAL THERAPEUTIC ENDOSCOPY WORKSHOPS – “ENDOSCOPY”

(Organised by the Malaysian Society of Gastroenterology and Hepatology in collaboration with the University of Malaya)

EVENT	FACULTY	DATE
Difficult ERCP- “The Master’s Approach”	Kees Huibregtse (Amsterdam, The Netherlands)	19 th August 1993
Endoscopic Ultrasonography	TL Tio (Washington, USA)	26 th July 1994
ERCP- “Basic Skills, Finer Points and New Techniques”	Kees Huibregtse (Amsterdam, The Netherlands)	25 th August 1994
Practical Points in Therapeutic Endoscopy	Nib Soehendra (Hamburg, Germany)	6 th December 1994
Therapeutic Endoscopy Workshop (In conjunction with Island Hospital, Penang, Malaysia)	Nib Soehendra (Hamburg, Germany) Kees Huibregtse (Amsterdam, Netherlands)	22 nd July 1997
Lasers in Gastroenterology	R Leicester (London, United Kingdom)	13 th August 1997
GI Endoscopy Nurses Workshop – “Setting the Standards for Practice”	Staff Members - Endoscopy Unit, University Hospital, Kuala Lumpur, Malaysia	30 th April - 2 nd May 1999
Endoscopy 2000	Sydney C S Chung (Hong Kong, China), Kenji Yasuda (Kyoto, Japan), Wang Yong-Guang (Beijing, China), Nageshwar Reddy (Hyderabad, India) <i>GIA Faculty:</i> Dorothy Wong (Hong Kong, China)	13 th - 15 th April 2000
Endoscopy 2001 – “A Master Class in Therapeutic Endoscopy”	Nib Soehendra (Hamburg, Germany) <i>GIA Faculty:</i> Adriana Cargin (Melbourne, Australia)	14 th - 15 th April 2001
Endoscopy 2002 – “Enhancing Basic Skills and Developing Expertise”	Christopher Williams (London, United Kingdom), Naotaka Fujita (Sendai, Japan), Joseph Leung (Sacramento, USA), Kees Huibregtse (Amsterdam, Netherlands) <i>GIA Faculty:</i> Diana Jones (Sydney, Australia)	5 th - 7 th April 2002
Endoscopy 2003 – “The Cutting Edge of GI Endoscopy”	Douglas Howell (Portland, USA), Haruhiro Inoue (Tokyo, Japan) Simon K Lo (Los Angeles, USA), Nageshwar Reddy (Hyderabad, India)	28 th February - 2 nd March 2003
Endoscopy 2004 – “Appreciating the Art of GI Endoscopy”	Firas Al Kawas (Washington, USA), Yoshihiro Sakai (Tokyo, Japan), Stefan Seewald (Hamburg, Germany), Joseph Sung (Hong Kong, China)	5 th - 7 th March 2005
Endoscopy 2005 – “Defining the Scope of Excellence”	Guido Costamagna (Rome, Italy), Shim Chan-Sup (Seoul, South Korea), K Yasuda (Kyoto, Japan), B Rembacken (Leeds, United Kingdom)	1 st - 3 rd April 2005
Endoscopy 2006 – “Frontiers of Therapeutic Endoscopy”	A T R Axon (Leeds, United Kingdom), James Lau (Hong Kong, China), Seo Dong-Wan (Seoul, Korea), Irving Waxman (Chicago, USA), Naohisa Yahagi (Tokyo, Japan)	14 th - 16 th April 2006
Endoscopy 2007 – “The Best Endoscopic Practices	Nageshwar Reddy (Hyderabad, India), Reza Shaker (Milwaukee, USA), Yusuke Saitoh (Sapporo, Japan), Stefan Seewald (Hamburg, Germany), Song Si-Young (Seoul, Korea), Mary Bong (Sydney, Australia)	13 th - 15 th April 2007
Endoscopy 2008 – “Seeing Better, Doing Better”	Peter B Cotton (Charleston, USA), G Ginsberg (Philadelphia, USA), H Isayama (Tokyo, Japan), S Ryozaawa, (Yamaguchi, Japan), J S Byeon (Seoul, Korea), Syed Shah, (West Yorkshire, United Kingdom)	29 th February, 1 st - 2 nd March 2008
Endoscopy 2009 – “Exploring the Limits of Endoscopy”	Jerome D Wayne (New York, USA), Kulwinder Dua (Milwaukee, USA), Amit Maydeo (Mumbai, India), H Kawamoto (Okayama, Japan), I Yasuda (Gifu, Japan), Lee Yong-Chan (Seoul, Korea), Y Sano (Kobe, Japan)	20 th - 22 nd March 2009

ANNUAL THERAPEUTIC ENDOSCOPY WORKSHOPS – “ENDOSCOPY” (CONT'D)

(Organised by the Malaysian Society of Gastroenterology and Hepatology in collaboration with the University of Malaya)

EVENT	FACULTY	DATE
Endoscopy 2010 (organised with the APDW 2010) (In conjunction with Selayang Hospital, Kuala Lumpur, Malaysia)	Michael Bourke (Sydney, Australia), David Carr-Locke (New York, USA), Mitsuhiro Fujishiro (Tokyo, Japan), Marc Giovannini (Marseilles-France), Takuji Gotoda (Tokyo, Japan), James Lau (Hong Kong, China), Amit Maydeo (Mumbai, India), Ibrahim Mostafa (Cairo, Egypt), Horst Neuhaus (Düsseldorf, Germany), Nageshwar Reddy (Hyderabad, India), Rungsun Reknimitr (Bangkok, Thailand), Seo Dong-Wan (Seoul, Korea), Naohisa Yahagi (Tokyo, Japan), Hironori Yamamoto (Tokyo, Japan), Kenjiro Yasuda (Kyoto, Japan)	20 th - 21 st September 2010
Endoscopy 2011 – “What’s New and What’s Good for Our Patients”	Hisao Tajiri (Tokyo, Japan), Chiu Han-Mo (Taipei, Taiwan), Arthur Kaffes (Sydney, Australia), Ho Khek-Yu (Singapore), Hiroo Imazu (Tokyo, Japan), Takao Itoi (Tokyo, Japan), Lee Dong-Ki (Seoul, Korea), Takahisa Matsuda (Tokyo, Japan), Moon Jong-Ho (Seoul, Korea)	14 th - 17 th April 2011
Endoscopy 2012 – “Therapeutic Endoscopy in the Global World”	Robert Hawes (Miami, USA), Hiroshi Kashida (Kinki, Japan), Lee Sang-Hyup (Seoul, Korea), Claudio Navarette (Santiago, Chile), Paulo Sakai (Sao Paulo, Brazil), Rajvinder Singh (Adelaide, Australia), Wang Hsiu-Po (Taipei, Taiwan), Kenshi Yao (Fukuoka, Japan)	30 th - 31 st March, 1 st April 2012
Endoscopy 2013 – “Advancing the Practice of Endoscopy”	Phillip Chiu (Hong Kong, China), Lawrence Khek-Yu Ho (Singapore), Horst Neuhaus (Dusseldorf, Germany), Krish Ragunath (Nottingham, United Kingdom), Dong-Wan Seo (Seoul, Korea), Yun-Sheng Yang (Beijing, China), Ian Yusoff (Perth, Australia) <i>Special GIA Faculty:</i> Wang Ping (Shanghai, China)	12 th - 14 th April 2013
Endoscopy 2014 – “The Best Tips in Therapeutic Endoscopy”	Mitsuhiro Kida (Kanagawa, Japan), Gregory Ginsberg (Philadelphia, USA), Yutaka Saito (Tokyo, Japan), Jin Hong Kim (Suwon, Korea), James Y W Lau (Shatin, Hong Kong) <i>Special GIA Faculty:</i> Mary Bong (Sydney, Australia)	28 th - 30 th March 2014
Endoscopy 2015 – “Maintaining Quality in Endoscopy”	Christopher Khor (Singapore), Sundeep Lakhtakia (Hyderabad, India), Hiroyuki Maguchi (Sapporo, Japan), Amit Maydeo (Mumbai, India), Jong-Ho Moon (Bucheon, Korea), Roy Soetikno (Singapore and California, USA), Kenneth Wang (Rochester, Usa)	17 th - 19 th April 2015

DISTINGUISHED ENDOSCOPY LECTURERS

NO	YEAR	ORATOR	TOPIC
1 st	1999	Kees Huijbregtse (Amsterdam, The Netherlands)	The Development and Use of Biliary Endoprosthesis in ERCPs
2 nd	2001	Nib Soehendra (Hamburg, Germany)	A Master’s Approach to Therapeutic Endoscopy
3 rd	2002	Christopher Williams (London, United Kingdom)	Practical Tips and Pitfalls in Colonoscopy
4 th	2003	Guido N J Tytgat (Amsterdam, The Netherlands)	The Unlimited Horizons of Therapeutic Endoscopy
5 th	2004	Yoshio Sakai (Tokyo, Japan)	Development and Application of Colonoscopy
6 th	2005	Guido Costamagna (Rome, Italy)	Endoscopic Management of Pancreatobiliary Diseases – State-of-the-art in 2005
7 th	2006	Anthony T R Axon (Leeds, United Kingdom)	The Impact of New Technology in GI Endoscopy
8 th	2007	D Nageshwar Reddy (Hyderabad, India)	Chronic Pancreatitis – Genes to Bedside
9 th	2008	Peter Cotton (Charleston, USA)	Therapeutic Endoscopy – Then, Now and Maybe
10 th	2009	Jerome Waye (New York, USA)	Exploring the Limits of Endoscopy
11 th	2010	David L Carr-Locke (New York, USA)	Enhancing the Eye – The Future of Endoscopy
12 th	2011	Hisao Tajiri (Tokyo, Japan)	Enhanced Imaging of the Gastrointestinal Tract
13 th	2012	Robert Hawes (Orlando, USA)	The Current and Future Role of Endoscopic Ultrasonography in GI Practice
14 th	2013	Horst Neuhaus (Dusseldorf, Germany)	Viewing the Bile Duct – Recent Developments of Cholangioscopy
15 th	2014	Gregory Ginsberg (Philadelphia, USA)	Future Prospects for Gastrointestinal Endoscopy
16 th	2015	Kenneth Wang (Rochester, USA)	Diagnosis and Endoscopic Treatment of Barrett’s Esophagus

ANNUAL SCIENTIFIC MEETINGS – OVERSEAS INVITED FACULTY

The Stomach '96 (Co-organised with the College of Surgeons)

3rd – 6th July 1996, Kuala Lumpur

Stephen G Bown	United Kingdom	Kang Jin-Yong	United Kingdom	Henry M Sue-Ling	United Kingdom
Sydney C S Chung	Hong Kong	Lam Shiu-Kum	Hong Kong	Nicholas J Talley	Australia
Teruyuki Hirota	Japan	Adrian Lee	Australia	Guido N J Tytgat	Netherlands
Richard H Hunt	Canada	Roy E Pounder	United Kingdom	Cornelis J H Van De Velde	Netherlands
David Johnston	United Kingdom	Robert H Riddell	Canada		

Penang International Teaching Course in Gastroenterology

(Co-organised with Penang Medical Practitioners' Society with the participation of the British Society of Gastroenterology)

23rd – 26th July 1997, Penang

Anthony Axon	United Kingdom	Dermot Kelleher	Ireland	J J Misiewicz	United Kingdom
John Dent	Australia	Fumio Konishi	Japan	James Neuberger	United Kingdom
R Hermon Dowling	United Kingdom	John Lambert	Australia	Thierry Poynard	France
Greg Holdstock	United Kingdom	Michael Larvin	United Kingdom	Jonathan Rhodes	United Kingdom
Kees Huibregtse	Netherlands	Christopher Liddle	Australia	Nib Soehendra	Germany
P W N Keeling	Ireland	Lim Seng-Gee	Singapore		

Second Western Pacific Helicobacter Congress

25th – 27th July 1998, Kota Kinabalu, Sabah

Masahiro Asaka	Japan	Richard Hunt	Canada	Pentti Sipponen	Finland
Douglas E Berg	USA	Lam Shiu-Kum	Hong Kong, China	Joseph J Y Sung	Hong Kong, China
Fock Kwong-Ming	Singapore	Adrian Lee	Australia	Rakesh Tandon	India
David Forman	United Kingdom	Peter Malfertheiner	Germany	Guido N J Tytgat	Netherlands
David Y Graham	USA	Kenneth E L McColl	Scotland	Xiao Shu-Dong	China
Stuart L Hazell	Australia	Hazel M Mitchell	Australia		

Gastroenterology 1999

23rd – 25th July 1999, Kuala Terengganu, Terengganu

Francis K L Chan	Hong Kong, China	Mohammed Al Karawi	Saudi Arabia	Quak Seng-Hock	Singapore
Sydney S C Chung	Hong Kong, China	Mohammad Sultan Khuroo	Saudi Arabia	Nicholas J Talley	Australia
John Dent	Australia	Peter Malfertheiner	Germany	Neville D Yeomans	Australia
Rikiya Fujita	Japan	Colm O'Morain	Ireland		

GUT 2000

24th – 26th August 2000, Melaka

Anthony Axon	United Kingdom	Lim Seng-Gee	Singapore	Francis Seow-Choen	Singapore
Geoffrey C Farrell	Australia	Anthony I Morris	United Kingdom	Jose D Sollano	Philippines
Vay Liang W Go	USA	David Mutimer	United Kingdom	Guido N J Tytgat	Netherlands
Humphrey J F Hodgson	United Kingdom	Ng Han-Seong	Singapore	Michael Wolfe	USA
Peter Katelaris	Australia	Thierry Poynard	France		

Gastro 2001 (With the participation of the American Gastroenterological Association)

5th – 8th April 2001, Kota Kinabalu, Sabah

Aziz Rani	Indonesia	Y K Joshi	India	Mahesh P Sharma	India
Chung Owyang	USA	Joseph Kolars	USA	Gurkirpal Singh	USA
Sydney S C Chung	Hong Kong, China	Koo Wen-Hsin	Singapore	Jose D Sollano	Philippines
Andrew Clouston	Australia	Edward Krawitt	USA	J L Sweeney	Australia
John Dent	Australia	Pinit Kullavanijaya	Thailand	Rakesh Tandon	India
Fock Kwong-Ming	Singapore	Lam Shiu-Kum	Hong Kong, China	Benjamin C Y Wong	Hong Kong, China
Robert N Gibson	Australia	Peter Malfertheiner	Germany	Xiao Shu-Dong	PR China
Richard Hunt	Canada	James M Scheiman	USA		

ANNUAL SCIENTIFIC MEETINGS –
OVERSEAS INVITED FACULTY (CONT'D)

GUT 2002**27th – 30th June 2002, Penang**

Chow Wan-Cheng	Singapore	Peter Katelaris	Australia	Ng Han-Seong	Singapore
Anuchit Chutaputti	Thailand	James Y W Lau	Hong Kong, China	C S Pitchumoni	USA
David Forman	United Kingdom	Tore Lind	Sweden	Herbert J Tilg	Austria
Lawrence Ho Khek-Yu	Singapore	Barry James Marshall	Australia	John Wong	Hong Kong, China

GUT 2003**28th – 31st August 2003, Kuching, Sarawak**

Francis K L Chan	Hong Kong, China	Humphrey J O'Connor	Ireland	Eamonn M M Quigley	Ireland
Chang Mei-Hwei	Taiwan	Colm O'Morain	Ireland	Jose D Sollano Jr	Philippines
W G E Cooksley	Australia	Teerha Piratvisuth	Thailand	Joseph Sung	Hong Kong, China
Gwee Kok-Ann	Singapore	Roy Pounder	United Kingdom	Yeoh Khay-Guan	Singapore

GUT 2004**24th – 27th June 2004, Penang**

Sydney C S Chung	Hong Kong, China	Huang Jia-Qing	China	Mario Rizzetto	Italy
Geoffrey C Farrell	Australia	Lam Shiu-Kum	Hong Kong, China	Russell W Strong	Australia
Ronnie Fass	USA	Peter W R Lee	United Kingdom	Benjamin C Y Wong	Hong Kong, China
David Fleischer	USA	Masao Omata	Japan		
Fock Kwong-Ming	Singapore	Teerha Piratvisuth	Thailand		

GUT 2005**23rd – 25th June 2005, Pulau Langkawi, Kedah**

Raymond Chan Tsz-Tong	Hong Kong, China	Gerald Johannes Holtmann	Australia	Graeme Young	Australia
Meinhard Classen	Germany	Peter Malferteiner	Germany	Yuen Man-Fung	Hong Kong, China
Anthony Goh	Singapore	Kenneth McColl	Ireland		

GUT 2006**20th – 23rd June 2006, Kuala Lumpur**

Peter Gibson	Australia	Anthony Morris	United Kingdom	Francis Seow-Choen	Singapore
Lawrence Ho Khek-Yu	Singapore	Nageshwar Reddy	India	Nimish Vakil	USA
Gerald Johannes Holtmann	Germany	Ng Han-Seong	Singapore	John Wong	Hong Kong, China
Lim Seng-Gee	Singapore	Ooi Choon-Jin	Singapore		
Irvin Modlin	USA	Fred Poordad	USA		

GUT 2007**29th August – 1st September 2007, Kota Kinabalu, Sabah**

Ronnie Fass	USA	Norman Marcon	USA	Nib Soehendra	Germany
Marc Giovannini	France	Amit Maydeo	India	Daniel Wong	Singapore
Robert Hawes	USA	Charlie Millson	England	Hironori Yamamoto	Japan
Richard Hunt	Canada	G V Rao	India	Yeoh Khay-Guan	Singapore
Finlay Macrae	Australia	Marcelo Silva	Argentina		

GUT 2008**21st – 24th August 2008, Kuala Lumpur**

Anuchit Chutaputti	Thailand	Lawrence Ho Khek-Yu	Singapore	Govind K Makharia	India
Peter Bytzer	Sweden	Pali Hungin	United Kingdom	Prateek Sharma	USA
Henry Chan Lik-Yuen	Hong Kong, China	Rupert Leong	Australia	Rajvinder Singh	Australia
Sydney C S Chung	Hong Kong, China	Davide Lomanto	Singapore	Mitchell Shiffman	USA
David Y Graham	USA	Lui Hock-Foong	Singapore	Sundee Punamiya	Singapore

**ANNUAL SCIENTIFIC MEETINGS –
OVERSEAS INVITED FACULTY (CONT'D)**

GUT 2009

14th to 16th August 2009, Pulau Langkawi, Kedah

Geoffrey Farrell	Australia	Lim Seng-Gee	Singapore	Joseph Sung Jao-Yiu	Hong Kong, China
Fock Kwong-Ming	Singapore	Lo Chung-Mau	Hong Kong, China	Daniel Wong Wai-Yan	United Kingdom
Peter R Galle	Germany	Irvin Modlin	USA	Yeoh Khay-Guan	Singapore
Christopher Khor	Singapore	Fabio Pace	Italy		
George K K Lau	Hong Kong, China	Rungsun Rerknimitr	Thailand		

APDW 2010 (Incorporating GUT 2010 & Endoscopy 2010)

19th to 22nd September 2010, Kuala Lumpur Convention Centre, Kuala Lumpur

Subrat Kumar Acharya	India	Hiroyuki Isayama	Japan	Eamonn Quigley	Ireland
Deepak Amarapurkar	India	Takao Itoi	Japan	Shanmugarajah Rajendra	Australia
Ang Tiing-Leong	Singapore	Derek Jewell	United Kingdom	Gurudu Venkat Rao	India
John Atherton	United Kingdom	Jia Ji-Dong	China	Nageshwar Reddy	India
Anthony Axon	United Kingdom	Utom Kachintorn	Thailand	Rungsun Rerknimitr	Thailand
Deepak Bhasin	India	Hiroshi Kashida	Japan	Jean Francois Rey	France
Henry J Binder	USA	Peter Katelaris	Australia	Shomei Ryozaawa	Japan
Mary Bong	Australia	Takashi Kawai	Japan	Yutaka Saito	Japan
Michael Bourke	Australia	Christopher Khor Jen-Lock	Singapore	Shiv Sarin	India
Marco Bruno	The Netherlands	Nayoung Kim	Korea	Wolff Schmiegel	Germany
David Carr-Locke	USA	Seigo Kitano	Japan	Juergen Schoelmerich	Germany
Ashok Chacko	India	Sriram Krishnan	USA	See Teik-Choon	United Kingdom
Henry Chan Lik-Yuen	Hong Kong, China	Shin-ei Kudo	Japan	Seo Dong-Wan	Korea
Francis Chan Ka-Leung	Hong Kong, China	Ashish Kumar	India	Francis Seow-Choen	Singapore
Adarsh Chaudhary	India	George Lau	Hong Kong, China	Prateek Sharma	USA
Yogesh Chawla	India	James Lau Yun-Wong	Hong Kong, China	Shim Chan-Sup	Korea
Yang Chen	USA	Rupert Leong	Australia	Hiroshi Shimada	Japan
Chen Min-Hu	China	Leung Wai-Keung	Hong Kong, China	Jose Sollano	Philippines
Philip Chiu	Hong Kong, China	Lim Seng-Gee	Singapore	Eduard Stange	Germany
Pierce Chow	Singapore	Lin Jaw-Town	Taiwan	Russell W Strong	Australia
Chow Wan-Cheng	Singapore	Liu Chen-Hua	Taiwan	Kentaro Sugano	Japan
Sylvia Crutchet	Chile	Lo Chung-Mau	Hong Kong, China	Kazuki Sumiyama	Japan
J Enrique Dominguez-Muñoz	Spain	Lo Gin-Ho	Taiwan	Joseph Sung	Hong Kong, China
Greg Dore	Australia	Anna Lok Suk-Fong	USA	Hisao Tajiri	Japan
Christophe DuPont	France	Kaushal Madan	India	Nicholas Joseph Talley	Australia
Anders Ekbohm	Sweden	Varocha Mahachai	Thailand	Narci Teoh	Australia
Geoffrey Charles Farrell	Australia	Govind Makharia	India	Judith Tighe-Foster	Australia
Ronnie Fass	USA	Peter Malfertheiner	Germany	Guido Tytgat	The Netherlands
Fock Kwong-Ming	Singapore	Takahisa Matsuda	Japan	Noriya Uedo	Japan
Ruggiero Francavilla	Italy	Amit Maydeo	India	James Versalovic	USA
Mitsuhiro Fujishiro	Japan	Kenneth E L McColl	United Kingdom	Wang Hsiu-Po	Taiwan
Peter Galle	Germany	Paul Moayyedi	Canada	William E Whitehead	USA
Edward Gane	New Zealand	Irvin Modlin	USA	Simon Wong Kin-Hung	Hong Kong, China
Uday Ghoshal	India	Moon Jong-Ho	Korea	Benjamin Wong Chun-Yu	Hong Kong, China
Peter Gibson	Australia	Ibrahim Mostafa	Egypt	Justin Wu	Hong Kong, China
Marc Giovannini	France	Horst Neuhaus	Germany	Naohisa Yahagi	Japan
Takuji Gotoda	Japan	Masao Omata	Japan	Hironori Yamamoto	Japan
Gwee Kok-Ann	Singapore	Evan Ong	Philippines	Ichiro Yasuda	Japan
Robert Heading	United Kingdom	Ooi Choon-Jin	Singapore	Kenjiro Yasuda	Japan
Janaki Hewavisenthi	Sri Lanka	Park Hyo-Jin	Korea	Neville Yeomans	Australia
Lawrence Ho Khek-Yu	Singapore	Teerha Piratvisuth	Thailand	Graeme Young	Australia
Bing Hu	China	Ronnie Poon	Hong Kong, China	Yu Ming-Lung	Taiwan
Pali Hungin	United Kingdom	Sundeepp Punnamiya	Singapore	Yuen Man-Fung	Hong Kong, China
Richard Hunt	Canada	Qian Jia-Ming	China	Qi Zhu	China

**ANNUAL SCIENTIFIC MEETINGS -
OVERSEAS INVITED FACULTY (CONT'D)**

GUT 2011**27th to 29th May 2011, Kuala Lumpur**

Ling Khoon-Lin	Singapore	Chan See-Ching	Hong Kong, China	See Teik-Choon	United Kingdom
Luigi Bolondi	Italy	Colm O'Morain	Ireland	Kao Jia-Hong	Taiwan
Lui Hock-Foong	Singapore	Philip Chiu Wai-Yan	Hong Kong, China	Yeoh Khay-Guan	Singapore
Hiroto Miwa	Japan	Ooi Choon-Jin	Singapore	George K K Lau	Hong Kong, China
Sybille Mazurek	Germany	Kang Jin-Yong	United Kingdom		

GUT 2012**29th June to 1st July 2012, Melaka**

Henry Chan Lik-Yuen	Hong Kong, China	James Y W Lau	Hong Kong, China	Morris Sherman	Canada
Emad El-Omar	USA	Francesco Marotta	Italy	Shaw Somers	United Kingdom
Han Kwang-Hyub	Korea	Ravi Mohanka	India	Jose Decena Sollano	Philippines
Lawrence Ho Khek-Yu	Singapore	D Nageshwar Reddy	India	Jan Tack	Belgium
Richard Kozarek	USA	Jinsil Seong	Japan	Wong Ka-Tak	Hong Kong, China

GUT 2013**23rd to 25th August 2013, Penang**

Alan Barkun	Canada	David Kwon	Korea	Takeshi Sano	Japan
Francis Chan	Hong Kong, China	Kenneth EL McColl	United Kingdom	Francis Seow-Choen	Singapore
Chien Rong-Nan	Taiwan	Ng Siew-Chien	Hong Kong, China	Vijay Shah	USA
Pierce Chow	Singapore	David Peura	USA	Justin Wu Che-yuen	Hong Kong, China
Michael A Kamm	Australia	Bjorn Rembacken	United Kingdom		

GUT 2014 & ECCO Educational Workshop**22nd to 24th August 2014, Kuala Lumpur**

Adarsh Chaudhary	India	Nancy Leung	United Kingdom	Stephan Vavricka	Switzerland
Janaka De Silva	Sri Lanka	Michael Manns	Germany	John A Windsor	New Zealand
Laurence Egan	Ireland	Jong-Ho Moon	Korea	Grace Wong Lai Hung	Hong Kong, China
Alexander Ford	United Kingdom	Nam Quoc Nguyen	Australia		
Patrick Kamath	USA	Nimish Vakil	USA		

MSGH ORATION LECTURERS

NO	YEAR	ORATOR	TOPIC
1 st	2001	P Kandasami Kuala Lumpur, Malaysia	Gastroenterology in Malaysia
2 nd	2002	Barry J Marshall Perth, Australia	<i>Helicobacter pylori</i> : How it all came about and where do we go from here?
3 rd	2003	Guido J Tytgat Amsterdam, The Netherlands	Future Developments in Gastroenterology
4 th	2004	Lam Shiu-Kum Hong Kong, China	Pathogenesis of Gastric Cancer – A Unifying Concept
5 th	2005	Meinhard Classen Munich, Germany	GI Cancer – The Global Burden in the New Millennium
6 th	2006	John Wong Hong Kong, China	Multi-Disciplinary Treatment in Esophageal Cancer: The Price of Failure
7 th	2007	Norman Marcon Toronto, Canada	New Optical Technologies for Early Detection of Dysplasia
8 th	2008	Sydney Chung Hong Kong, China	Ulcer Bleeding: What you really want to know
9 th	2009	Geoffrey Farrell Canberra, Australia	Battling the Bulge in Asia – Implications for Gastroenterologists
10 th	2010	Nicholas Joseph Talley Newcastle, Australia	New Insights into the Aetiopathogenesis of Functional Dyspepsia
11 th	2011	Colm O'Morain Dublin, Ireland	Colorectal Cancer – The Emerging Cancer in the 21 st Century
12 th	2012	Richard Kozarek Seattle, USA	Minimally Invasive/Interventional Gastroenterology: Where Have We Been? Where Are We Going?
13 th	2013	Goh Khean Lee Kuala Lumpur, Malaysia	Asia at the Crossroads: Changing Patterns and Emerging Diseases
14 th	2014	Patrick Kamath Minnesota, USA	Insights into Optimal Management of End Stage Liver Disease - A Continuing Challenge

PANIR CHELVAM MEMORIAL LECTURERS

NO	YEAR	ORATOR	TOPIC
1 st	2004	Mohd Ismail Merican Kuala Lumpur, Malaysia	Treatment of Chronic Viral Hepatitis in the Asia-Pacific Region: Realities and Practical Solutions
2 nd	2005	Peter Malfertheiner Magdeburg, Germany	Diagnosis and Management of Pancreatic Cancer
3 rd	2006	Nageshwar Reddy Hyderabad, India	GI Endoscopy in India – Development and Lessons for the Future
4 th	2007	Richard Hunt Hamilton, Canada	Evidence-based Medicine in the Real World
5 th	2008	Pali Hungin Durham, United Kingdom	Plausible Solutions for Impossible Problems
6 th	2009	Fock Kwong-Ming Singapore	Lower GI Bleeding – Epidemiology and Management
7 th	2010	Joseph J Y Sung Hong Kong, China	The Future Role of the Gastroenterologist in Digestive Oncology
8 th	2011	Kang Jin-Yong London, United Kingdom	East-West Differences in Upper GI Diseases
9 th	2012	Emad El-Omar Aberdeen, United Kingdom	Role of Chronic Inflammation in GI Cancer
10 th	2013	Michael Kamm Melbourne, Australia	Achieving the Balance between Drug Therapy and Surgery in Inflammatory Bowel Disease
11 th	2014	John A Windsor Auckland, New Zealand	Progress with Acute Pancreatitis – Millstones and Milestones

CONFERENCE INFORMATION

CONGRESS SECRETARIAT

GUT 2015

G-1 Medical Academies of Malaysia

210 Jalan Tun Razak, 50400 Kuala Lumpur, Malaysia

Tel (+603) 4025 3700, 4025 4700, 4023 4700 Fax (+603) 4023 8100

Email secretariat@msggh.org.my Website www.msggh.org.my

REGISTRATION

The registration hours are:

20 th August 2015 (Thursday)	1600 to 1830 hrs
21 st August 2015 (Friday)	0730 to 1700 hrs
22 nd August 2015 (Saturday)	0730 to 1700 hrs

IDENTITY BADGES

Delegates are kindly requested to wear identity badges during all sessions and functions.

ENTITLEMENTS

Delegates are entitled to:

- All Scientific Sessions
- All Satellite Symposia
- Conference bag and materials
- Coffee / Tea
- Lunches
- Admission to the Trade Exhibition area

MEET-THE-EXPERT BREAKFAST SESSIONS

Please obtain the vouchers to attend these sessions from the Congress Secretariat. The charge is RM 30 per person per session.

SPEAKERS AND PRESENTERS

All speakers and presenters are requested to check into the Speaker Ready Room at least two hours prior to their presentation. There will be helpers on duty to assist with your requirements regarding your presentation.

20 th August 2015 (Thursday)	1600 to 1830 hrs
21 st August 2015 (Friday)	0730 to 1700 hrs
22 nd August 2015 (Saturday)	0730 to 1700 hrs
23 rd August 2015 (Sunday)	0730 to 1100 hrs

All presentations will be deleted from the conference computers after the presentations are over.

POSTERS

Posters will be displayed at the foyer from 0700 hrs on 21st August 2015 till 1200 hrs on 23rd August 2015.

PHOTOGRAPHY & VIDEOTAPING POLICIES

No photography or videotaping of the presentations is permitted during the scientific sessions.

MOBILE PHONES

For the convenience of all delegates, please ensure that your mobile phone is put on "Silence" mode during the conference sessions.

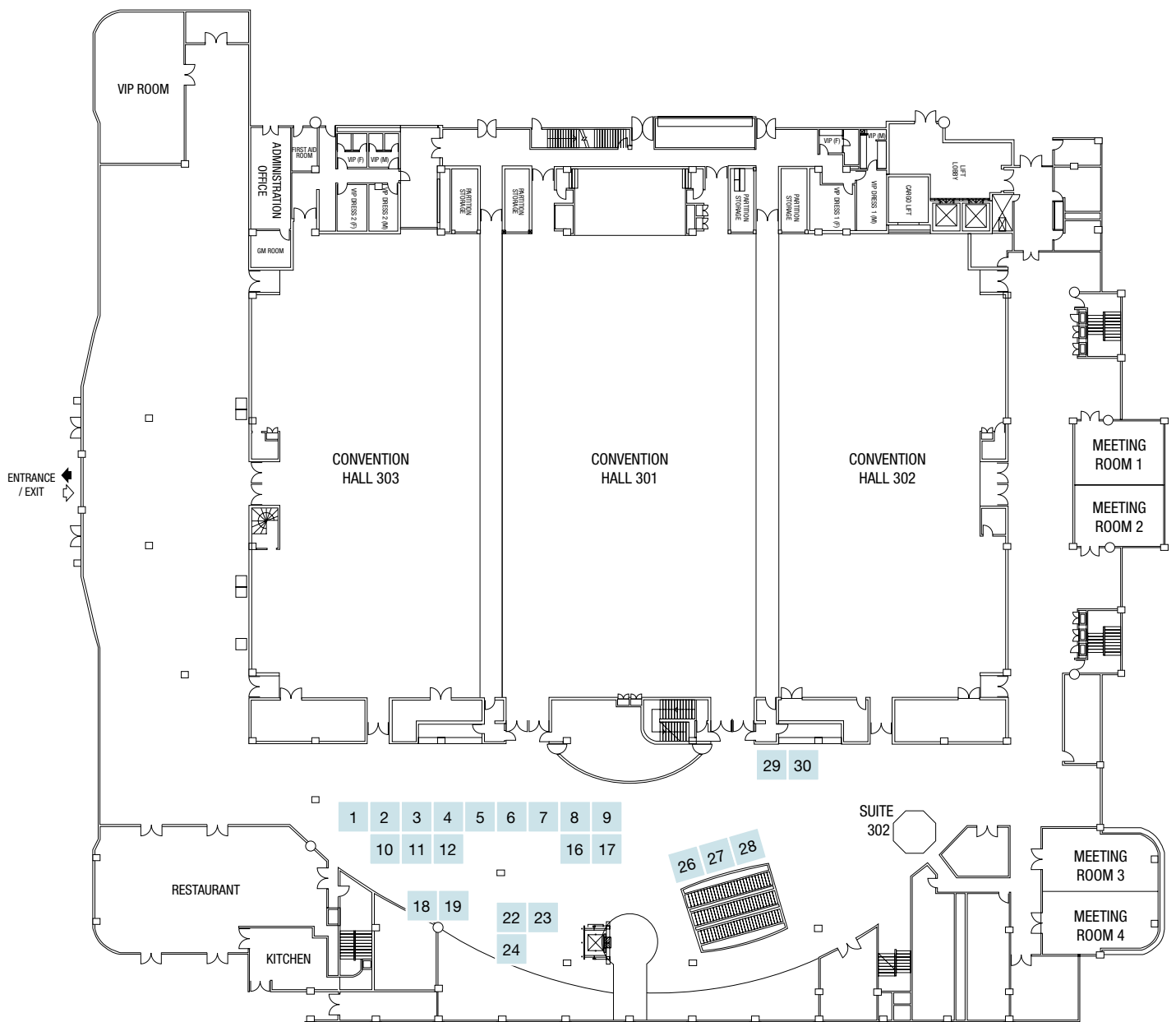
LIABILITY

The Organising Committee will not be liable for personal accidents, loss or damage to private properties of participants during the conference. Participants should make own arrangements with respect to personal insurance.

DISCLAIMER

Whilst every attempt would be made to ensure that all aspects of the Conference as mentioned in this publication will take place as scheduled, the Organising Committee reserves the right to make last minute changes should the need arises.

FUNCTION ROOMS & TRADE EXHIBITION



BOOTH STAND	COMPANY
1 & 10	Abbott Laboratories (M) Sdn Bhd
2	Technology Medical Associate Sdn Bhd
3	DKSH Malaysia Sdn Bhd
4 & 5	Janssen
6 & 7	Wellmedic Healthcare Sdn Bhd
8 & 9	Takeda Malaysia Sdn Bhd
11 & 12	LF Asia (M) Sdn Bhd
16 & 17	Novartis Corporation (M) Sdn Bhd
18	MEDA Rottapharm Madaus
19	Bayer Co (Malaysia) Sdn Bhd
22	Eisai Malaysia Sdn Bhd
23	All Eights (M) Sdn Bhd
24	Boston Scientific Malaysia Sdn Bhd
26, 27 & 28	Abbvie Sdn Bhd
29 & 30	AstraZeneca Sdn Bhd

ACKNOWLEDGEMENTS

The Organising Committee of the GUT 2015 expresses its deep appreciation to the following for their support and contribution to the success of the conference:

Abbott Laboratories (M) Sdn Bhd

Abbvie Sdn Bhd

All Eights (M) Sdn Bhd

AstraZeneca Sdn Bhd

Bayer Co (Malaysia) Sdn Bhd

Boston Scientific Malaysia Sdn Bhd

CCM Pharmaceutical Sdn Bhd

DKSH Malaysia Sdn Bhd

Eisai Malaysia Sdn Bhd

Janssen

LF Asia (M) Sdn Bhd

MEDA Rottapharm Madaus

Novartis Corporation (M) Sdn Bhd

Reckitt Benckiser

Takeda Malaysia Sdn Bhd

Technology Medical Associate Sdn Bhd

UG Medical

Wellmedic Healthcare Sdn Bhd

Lecture 1

HELICOBACTER PYLORI AND GASTRIC CANCER: A BALANCED VIEW**Kentaro Sugano**

Jichi Medical University, Shimotsuke, Japan

In 1994, International Agency for Research on Cancer (IARC) announced that *Helicobacter pylori* (*H. pylori*) is a group I (definite) carcinogen based on epidemiological evidence. This statement was confirmed by the second IARC monograph (100B), in which the link between *H. pylori* and gastric cancer was further strengthened by new lines of evidence including carcinogenic effects of *H. pylori* in animal models and a number of clinical reports demonstrating preventive effects of eradication on the development of gastric cancer. In Mongolian gerbils, for example, several groups reported that *H. pylori* caused gastric cancers after more than one year. A meta-analysis of several retrospective studies and one double-blind prospective study demonstrated that eradication therapy reduced the risk of gastric cancer. Then, *H. pylori* infection can be considered as a sufficient cause of gastric cancer and hence eradication of *H. pylori* can prevent gastric cancer? The answer is no at present. Indeed, IARC monograph 100B admitted that cancer in the gastric cardia which is increasing in Western countries has a different etiology as it is negatively associated with *H. pylori* infection. In epidemiological studies, there are puzzling data questioning the role of *H. pylori* on gastric carcinogenesis. For example, why duodenal ulcer (DU) patients rarely develop gastric cancer as compared with gastric ulcer (GU) patients despite of *H. pylori* infection? Why gastric cancer incidence and mortality are low in South-Eastern Asian or African countries where *H. pylori* prevalence is high (so-called Asian or African Enigma)? Furthermore, it has been repeatedly documented that gastric cancer risk still remains after eradication of *H. pylori*. Thus, it seems reasonable to assume that factors other than *H. pylori* infection are operative in promoting or initiating gastric carcinogenesis. One of the key factors would be acid secretion considering the following data. (1) Gastric cancer occurrence sharply increases in patients with advanced atrophy. (2) In South-Eastern Asian countries, advanced atrophy is not prevalent. (3) Patients with DU have higher acid secretory capacity than GU patients. (4) After eradication of *H. pylori*, advanced atrophy was demonstrated as an important predictor of gastric cancer development. It is well known that low acidity in the stomach allows bacterial overgrowth. Among the gastric bacteria isolated from the stomach, some are proinflammatory and may produce carcinogenic nitrosamines. Assuming such additional factors, many puzzling questions concerning the *H. pylori* infection and gastric cancer can be dissolved. Importantly, it will provide a rationale for recommending eradication therapy before development of atrophy and intestinal metaplasia, as agreed in Kyoto consensus meeting.

Symposium 2

Colorectal

COLORECTAL CANCER SCREENING – THE CHALLENGES AND PITFALLS**Yeoh Khay Guan**

Department of Medicine, Yong Loo Lin School of Medicine, National University of Singapore, Singapore

Colorectal cancer (CRC) is the 3rd most common cancer in the world with 1.4 million new cases each year. Screening of CRC is widely endorsed and the studies have shown all standard options for CRC screening can reduce mortality and incidence, and is cost-effective in average risk individuals. However, implementation of CRC screening is challenging and the results vary. Different approaches have been advocated taking into consideration various policies, resources and cultures. The main challenges limiting the effective implementation of CRC screening in many countries are population compliance and resource limitations. Some strategies such as risk stratification to differentiate risk in the population are potentially useful to improve cost-effectiveness.

In Singapore CRC is the most common cancer. The average population risk for developing CRC in Singapore is among the highest in the world. The age-standardised rates (ASR) for 2013 were 38.7 per 100,000 per year and 26.3 per 100,000 per year for men and women respectively. The national CRC screening programme was started in 2011. About 33.8% of Singaporeans aged 50-69 years old reported screening for CRC with either FIT or colonoscopy within the recommended timeframe in 2013. In this talk, we will discuss the challenges in implementation of CRC screening and share our experience in Singapore.

Symposium 2

Colorectal

COLONIC ADENOMA SURVEILLANCE*Leung Wai Keung*

Department of Medicine, University of Hong Kong, Hong Kong

While colonic adenoma is a precursor of colonic adenocarcinoma, patients found to have colonic adenoma would require surveillance colonoscopy at different time intervals depending on the number, histology and size of the lesions. In general, subjects with more than 3 adenomas, adenoma >1 cm or adenoma with villous features or high-grade dysplasia would necessitate an earlier colonoscopy. The presence of other risk factors, particularly family history of colorectal cancer (CRC) and personal history of CRC or inflammatory bowel disease, would also influence the surveillance intervals. Unlike screening for colorectal cancer (CRC), colonoscopy is the only recommended tool for surveillance purpose. The role of other techniques like CT colonography or fecal occult blood tests on surveillance of colonic adenoma remains to be determined. Due to the lack of quality data from randomized trials, the surveillance intervals of different colonic adenomas are largely based on expert opinions or consensus. Although there are many different recommendations issued by various professional societies, it remains to be proven in future studies whether these guidelines could be validated, particularly in Asian populations. There is also a tendency to prolong the surveillance intervals of those with negative baseline screening colonoscopy and low-risk colonic adenomas, which would free more colonoscopy capacity for screening of never screened individuals. With the increasing use of screening colonoscopy and detection of asymptomatic colonic adenoma, the volume and impact of surveillance colonoscopy on existing colonoscopy facilities and resources could not be overlooked.

Lecture 2

MANAGEMENT OF HCV RELATED CIRRHOSIS*K Rajender Reddy*

Ruimy Family President's Distinguished Professor of Medicine, University of Pennsylvania, Philadelphia, United States of America

Patients with advanced fibrosis and cirrhosis are most in need of HCV therapy, as successful therapy has been shown to decrease liver-related mortality. Interferon (IFN)-based antiviral treatment in these patients had been challenging due to patient tolerance, the risk of serious adverse events, and hypo-responsiveness to therapy. Bridging fibrosis and cirrhosis have traditionally been negative predictors of HCV treatment outcome. The disparity in sustained virological response (SVR) between cirrhotic and non-cirrhotic patients was evident during treatment with peginterferon (PEG-IFN) and RBV and was not mitigated by the addition of first generation protease inhibitors, boceprevir and telaprevir. The advent of all-oral DAA regimens considerably altered the treatment landscape by achieving superior tolerability as well as increased SVR rates despite truncated treatment durations. The combination of LDV/SOF with or without RBV given for 12 or 24 weeks has been evaluated in subsets of genotype 1 patients with cirrhosis in both treatment-naïve and treatment-experienced patients. The SVR in treatment-naïve patients ranged from 94% to 100%. In cirrhotic patients who had failed therapy, including a protease inhibitor, this regimen achieved an SVR of 82% to 100% with higher SVR rates noted with the 24-week regimen, regardless of the use of RBV. Further studies that were enriched with cirrhotic patients who had failed prior protease inhibitors show that 12 weeks of LDV/SOF with RBV has equal efficacy to 24 weeks of LDV/SOF.

In a trial exclusively for patients with cirrhosis who were treatment-naïve or prior PEG-IFN/RBV failures, the 3D regimen (paritaprevir/r [ritonavir boosted PI], ombitasvir [an NS5A inhibitor], and dasabuvir [a non-nucleoside inhibitor]), with RBV for 12 or 24 weeks achieved high SVR rates of 92% to 96%, respectively. Prior null responders and those with genotype 1a had a slightly lower numerical response of 87% and 89%, respectively, with a 12-week regimen, while the 24-week regimen achieved an SVR of 95% and 94%, respectively. Thus all-oral therapy for patients with HCV and cirrhosis has been a major advancement. Although many of the traditional treatment obstacles have been overcome and patients with cirrhosis can expect high SVR rates, challenges remain. Subsets of patients with cirrhosis, particularly those with prior treatment failure, will require a longer duration of therapy or other modifications, such as the addition of ribavirin, to maximize treatment response.

Case Discussion

LIVER NODULES*K Rajender Reddy*

Ruimy Family President's Distinguished Professor of Medicine, University of Pennsylvania, Philadelphia, United States of America

Incidentally discovered liver masses are an increasing phenomenon associated with the widespread use of imaging studies for diagnostic work up. A significant number of these “incidentalomas” are benign and require no intervention on the part of the physician. One of the greatest obstacles faced is the accurate diagnosis of such lesions, both to provide a measure of psychological comfort for patients as well as to ensure that a conservative approach is the appropriate one. The use of biopsy in diagnosing these tumors has been largely mitigated by the increased sensitivity and specificity of the various imaging modalities. New biomolecular and genetic criteria have allowed physicians to sub-classify many benign lesions in order to tailor patient care more appropriately; however, these markers are investigational and have not yet achieved the status of standard of care. Ultimately, the simple fact is that most individuals live and die with a benign liver tumor rather than from them, and minimizing unnecessary intervention is critical in providing the best possible care.

The differential diagnosis of an incidental hepatic mass must incorporate multifarious factors ranging from patient characteristics, history of hormonal and other drug therapies, comorbidities, and radiographic findings. The role of immunohistochemical and genetic markers needs to be explored further. Taken together, these data provide valuable clues that can help establish a definitive diagnosis and help guide patient management. It is prudent to employ follow up imaging before having the “knee-jerk” response of taking a biopsy of all lesions, due in part to the risk of bleeding and other complications associated with this procedure as well as the challenges of obtaining a reliable histologic diagnosis. Further, the vascular nature of many hepatic lesions, along with the fact that focal biopsies may not detect areas of malignancy in heterogeneous lesions, argue against routine use of a biopsy.

Recent observations have redefined the classification of several lesions and have concomitantly led to distinct recommendations for their care. Benign lesions should be managed conservatively whenever possible. Indications for surgical intervention include unmanageable symptoms, a high probability of complications such as hemorrhage and rupture, and the threat of malignant transformation. The treatment options generally outlined provide a frame work for dealing with benign hepatic tumors; however, in appropriately selecting a mode of therapy, the individual needs of the patient, and the availability of the local expertise, must always be considered as the over-arching guide to successful patient care.

Symposium 3

Microbiota

**THE GUT MICROBIOTA IN IRRITABLE BOWEL SYNDROME:
FRIEND OR FOE***Uday C Ghoshal*

Department of Gastroenterology, Sanjay Gandhi Postgraduate Institute of Medical Sciences, India

Progress in the understanding of the pathophysiology of irritable bowel syndrome (IBS), once thought to be a purely psychosomatic disease, has advanced considerably. Low-grade inflammation and changes in the gut microbiota now feature as potentially important in pathogenesis of IBS. The human gut harbours a huge microbial ecosystem, which is equipped to perform a variety of functions such as digestion of food, metabolism of drugs, detoxification of toxic compounds, production of essential vitamins, prevention of attachment of pathogenic bacteria to the gut wall, and maintenance of homeostasis in the gastrointestinal tract. A subset of patients with IBS may have a quantitative increase in bacteria in the small bowel (small intestinal bacterial overgrowth). Qualitative changes in gut microbiota have also been associated with IBS. Targeting the gut microbiota using probiotics and antibiotics has emerged as a potentially effective approach to the treatment of this, hitherto enigmatic, functional bowel disorder. The role of gut microbiota in health, quantitative and qualitative microbiota changes, and therapeutic manipulations targeting the microbiota in patients with IBS will be reviewed.

Symposium 3

Microbiota

MODULATING THE GUT MICROBIOTA IN IBD: DOES IT WORK?*Simon Travis*

Translational Gastroenterology Unit, Oxford University Hospital, United Kingdom

Probiotics are microorganisms that are ingested either in combination or as a single organism in an effort to normalize intestinal microbiota and potentially improve intestinal barrier function. Inflammatory bowel disease (IBD) may result from an inappropriate immunologic response to intestinal bacteria and a disruption in the balance of the gastrointestinal microbiota in genetically susceptible individuals. Prebiotics, synbiotics, and probiotics have all been studied as adjuncts to standard therapies for IBD. In general, probiotics have been shown to be well-tolerated with few side effects, making them a potential attractive treatment option in the management of IBD.

There have been 14 randomized controlled trials using probiotics, prebiotics, and/or synbiotics in patients with Crohn's disease (CD), 21 studies in patients with ulcerative colitis (UC), and 5 studies in patients with pouchitis. In patients with CD, studies comparing probiotics and placebo have shown no significant difference in clinical outcomes. Adding a probiotic to conventional treatment improved the overall induction of remission rates among patients with UC. There is benefit in maintaining remission in UC. Probiotics have also shown some efficacy in the treatment of pouchitis after antibiotic-induced remission.

There is insufficient evidence to recommend probiotics for use in CD. Probiotics have a role for induction and maintenance of remission in UC and pouchitis, particularly in patients intolerant of or minded to avoid conventional therapy. Faecal microbiota transplantation provides an alternate way of influencing the intestinal flora in IBD, but as yet this constitutes more hope than expectation.

References

1. Immune homeostasis, dysbiosis and therapeutic modulation of the gut microbiota. Peterson CT, Sharma V, Elmén L, Peterson SN. Clin Exp Immunol 2015;179:363-77.
2. The microbial basis of inflammatory bowel diseases. Dalal SR, Chang EB. J Clin Invest 2014;124:4190-6.
3. Mucosal barrier, bacteria and inflammatory bowel disease: possibilities for therapy. Merga Y, Campbell BJ, Rhodes JM. Dig Dis 2014;32:475-83
4. Manipulation of the microbiota for treatment of IBS and IBD-challenges and controversies. Shanahan F, Quigley EM. Gastroenterology 2014;146:1554-63.

Symposium 3

Microbiota

CURRENT TECHNIQUES FOR EVALUATING THE GUT MICROBIOME*Ujjala Ghoshal*

Sanjay Gandhi Postgraduate Institute of Medical Sciences, Lucknow, India

The human gastrointestinal tract is colonised by a complex community of microbes, which may have major impacts on host health. Three most dominant bacterial phyla are Firmicutes, Bacteroidetes, and Actinobacteria, while Proteobacteria and Verrucomicrobia are less abundant in the gut. Traditionally, culture based methods are used for study of this microbial ecosystem, but this has several limitations. Recently, microbial culturomics, a new concept based on using several culture conditions with identification by matrix assisted laser desorption ionization- time of flight followed by sequencing confer a new platform for study of gut flora. Culturomics approaches enable us to isolate 340 bacterial species including largest bacteria, virus and Archaea. Recent molecular techniques like real-time PCR are used for targeted approach for estimation of gut flora. High throughput DNA sequencing provides large number of sequences in a single run. Approximately, 80% of the bacteria found by molecular tools in the human gut are uncultured, and have been characterized by next generation sequencing (NGS). NGS revealed dominance of the Bacteroidetes phylum using 16S rDNA v4v5 region primers, whereas Firmicutes was predominant using v3v4 primers. Current threshold of the latest NGS method is 10⁵cfu/ml. Therefore, minor bacterial population *S. typhi*, *Yersinia enterocolitica*, and *Tropheryma whipplei* could not be identified. Thus, advancement in NGS may facilitate the analysis to low taxonomic level (genera, species) as well. In addition, nuclear magnetic resonance and high pressure liquid chromatography are upcoming exploratory tools for the study of gut ecosystem. In conclusion, culturomics, metabolomics and next generation sequencing have a crucial role in research of human gut microbiome.

Symposium 4

IBD

MUCOSAL HEALING AS THE NEW TARGET IN IBD MANAGEMENT: HOW FAR AND HOW DEEP SHOULD WE GO?

Simon Travis

Translational Gastroenterology Unit, Oxford University Hospital, United Kingdom

Mucosal healing has emerged as a key treatment goal in IBD that predicts sustained clinical remission and resection-free survival of patients. The structural basis of mucosal healing is an intact barrier function of the gut epithelium that prevents translocation of commensal bacteria into the mucosa and submucosa with subsequent immune cell activation. Mucosal healing should be considered as an initial event in the suppression of inflammation of deeper layers of the bowel wall, rather than as a sign of complete healing of gut inflammation.

Clinical studies on mucosal healing will be summarized and the effects of drugs such as 5-aminosalicylates, corticosteroids, azathioprine, ciclosporin, anti-TNF antibodies and anti-integrin therapy on mucosal healing discussed. Recent data on the longterm follow up of patients with ulcerative colitis achieving histological remission in addition to clinical and endoscopic remission will be presented, as well as international (STRIDE) guidelines on treatment targets for IBD.

Is the price worth paying? The downside of treatment escalation to achieve mucosal healing is as yet unknown, but at the very least it is clear that when mucosal healing has not been achieved, therapy should not be stopped.

References

1. Mucosal healing in IBD: a systematic review. Neurath MF, Travis SPL. Gut 2012;61:1619-1635. (Podcast <http://podcasts.bmj.com/themes/gut/mp3/gut-podcast-mucosal-healing.mp3>)
2. Mucosal healing as a target for therapy in colonic IBD and methods to score disease activity. Walsh A, Palmer R, Travis SPL. Gastrointestinal Endosc Clinics N America 2014;24:367-78.
3. Beyond endoscopic mucosal healing in UC: histological remission better predicts corticosteroid use and hospitalisation over 6 years of follow-up. Bryant RV, Burger DC, Delo J, Walsh AJ, Thomas S, von Herbay A, Buchel OC, White L, Brain O, Keshav S, Warren BF, Travis SPL. Gut 2015 epub May 18.
4. Selecting Therapeutic Targets in Inflammatory Bowel Disease (STRIDE): Determining Therapeutic Goals for Treat-to-Target. Peyrin Biroulet L, Sandborn WJ, Sands B, Reinisch W, Bemelman W, Bryant RV, D'Haens G, Dotan I, Dubinsky M, Feagan B, Fiorino G, Geary G, Krishnareddy S, Lakatos PL, Loftus Jr EV, Marteau P, Munkholm P, Murdoch T, Ordás I, Panaccione R, Riddell RR, Ruel R, Rubin DT, Samaan M, Siegel C, Silverberg M, Stoker J, Schreiber S, Travis SPL, Van Assche G, Panes J, Hanauer S, Colombel JF. Am J Gastroenterol 2015 (in press)

Symposium 4

IBD

OPTIMIZING THE QUALITY OF CARE FOR THE IBD PATIENT IN EVOLVING ECONOMIES

Leung Wai Keung

Department of Medicine, University of Hong Kong, Hong Kong

Inflammatory bowel disease (IBD) was once a rare disease in Asia. However, both the incidence and prevalence of IBD are rising rapidly in Asia resulting in a pressing need for quality care of IBD patients in this region. Optimal management of IBD requires expertise and is usually expensive. The goals of treatment have been evolved from short-term symptom control to long-term prevention of IBD related complications and even histological remission. There are, however, many barriers that limit the delivery of the best quality care to IBD patients in this region. First, a team effort including the contribution from gastroenterologists, colorectal surgeons, radiologists, dietitians and nurse specialists is required, which make it difficult for small units with limited resources. Second, the frequent use of endoscopic and radiological imaging for patients with IBD would have major impact on health care utilization and prioritization. Many laboratory tools useful in monitoring the disease is also not widely available in this region such as fecal calprotectin test, measurements of thiopurine metabolites and trough levels of biologics, etc. Third, new pharmacological treatments for IBD, particularly biologics, are costly and may not be covered by insurances or the national health care system in many Asian countries. There are major financial difficulties for many IBD patients to initiate or maintain on biologics. Despite the availability of biosimilars in some Asian countries, the actual cost saving is not substantial. Hence, there is a genuine need to characterize the role of other non-biologic agents in management of IBD in this region such as thalidomide, methotrexate or tacrolimus, etc. There are still a lot of tasks for the Asian IBD clinicians to accomplish and it is an exciting moment to witness the rapid changes in practices of IBD management in Asia.

HCV - PAST, PRESENT AND FUTURE***K Rajender Reddy***

Ruimy Family President's Distinguished Professor of Medicine, University of Pennsylvania, Philadelphia, United States of America

The therapeutic landscape for the treatment of chronic hepatitis C virus (HCV) infection has been rapidly evolving since the approval of the first direct-acting antiviral agents (DAAs), telaprevir and boceprevir, in 2011. In 2013, sofosbuvir (SOF) became the first nucleoside NS5B polymerase inhibitor to be approved and offered a potent DAA with a high genetic-barrier that led the transformation of HCV treatment to all-oral regimens. Over the last 2 years, several key all oral therapy regimens have become available for treating chronic HCV: (1) SOF plus ribavirin (RBV); (2) SOF plus simeprevir (SMV), an NS3 protease inhibitor; (3) the fixed-dose combination of SOF with the NS5A inhibitors ledipasvir (LDV/SOF) or DCV (daclatasvir); (4) a 3 DAA (3D) 3 RBV regimen (paritaprevir [NS3/4A protease inhibitor] boosted with ritonavir, ombitasvir [NS5A inhibitor], and dasabuvir [non-nucleoside NS5B polymerase inhibitor]). Daclatasvir, a pangenotypic NS5 AN inhibitor is available in most parts of the World and is an approved regimen along with asunaprevir, a protease inhibitor. The Phase 3 clinical trials provided guidance and informed clinicians about optimizing therapy with these drugs. However, not all patient scenarios can be anticipated, and often a more nuanced interpretation of Phase 3 trial results, coupled with rapidly evolving data from ongoing Phase 2 clinical trials, will also provide important information to guide practice. In 2013, the American Association for the Study of Liver Diseases (AASLD) and Infectious Diseases Society of America (IDSA)/International Antiviral Society USA (IAS-USA) formed a task force to provide ongoing treatment recommendations incorporating the most up-to-date clinical data and to serve as an additional resource for clinicians who manage patients with HCV. This guidance document is periodically updated and is a great resource for treating Physicians. The European Association for the Study of Liver Diseases (EASL) provides comprehensive guidelines as well.

Despite the advances, the current antiviral paradigm remains complex, with the need for an expert clinician to carefully consider multiple factors in guiding patients in treatment decisions, such as HCV genotype and/or subtype, stage of liver fibrosis, prior treatment experience, HIV co-infection, and liver disease status (eg, decompensation, liver cancer, post-transplant). However, it is anticipated that as treatment transitions to increasingly simple, short, and effective regimens which form the basis for "one size fits all" across genotypes and patient characteristics, that there will be a more readily accepting treating community of Physicians, an inevitable and necessary step in our goal of HCV eradication globally.

All-oral regimens have become the new standard of care for chronic HCV and have already demonstrated remarkable rates of SVR with well-tolerated, convenient dosing across a broad population of patients who previously could not tolerate nor benefit from IFN-based regimens. Despite the rapid accumulation of data and the prompt revisions of treatment recommendations, numerous questions regarding optimal management of certain populations and clinical scenarios remain unanswered.

Symposium 6

FGID

ESOPHAGEAL MOTILITY DISORDER - WHEN TO REFER***Rajesh Sainani***

Jaslok Hospital & HN Reliance Foundation Hospitals, Mumbai, India

High resolution manometry has revolutionized the way we evaluate and diagnose motility disorders of the esophagus. It has improved our interpretation and helped in management of various clinical conditions especially achalasia cardia.

Esophageal manometry is performed for evaluation of patients with dysphagia. Flexible endoscopy must be performed prior to esophageal manometry to exclude a mechanical cause.

When to refer a patient for esophageal motility disorder:

1. Evaluation of patients with non cardiac chest pain (normal cardiac evaluation normal endoscopy)
2. Evaluation of patients with dysphagia (with normal endoscopy)
3. Evaluation of patients with transfer dysphagia
4. Achalasia Cardia (dysphagia, regurgitation are predominant symptoms)
5. Spastic disorders (dysphagia and chest pain are common symptoms)
 - i. Distal esophageal spasm
 - ii. Jackhammer / Nutcracker esophagus
6. Ineffective Esophageal Peristalsis (Nonspecific esophageal motility disorders)
7. Evaluation of patients with gastroesophageal reflux disease
8. Prior to fundoplication to assess esophageal motility and lower esophageal sphincter pressures
9. Prior to placement of pH probe to localize lower esophageal sphincter pressures
10. Post operative:
 1. Post fundoplication dysphagia
 2. Post myotomy dysphagia
11. Connective tissue disorders [eg. Scleroderma disease]

BEST PAPER AWARD PRESENTATIONS

- OP 1 SILYMARIN FOR THE TREATMENT OF NON-ALCOHOLIC STEATOHEPATITIS: INTERIM ANALYSIS OF A RANDOMIZED, DOUBLE-BLIND, PLACEBO-CONTROLLED TRIAL** 34
Wah-Kheong Chan¹, Nik Raihan Nik Mustapha², Sanjiv Mahadeva¹
¹Department of Medicine, Faculty of Medicine, University of Malaya, Kuala Lumpur, Malaysia
²Department of Pathology, Hospital Sultanah Bahiyah, Alor Setar, Kedah, Malaysia
- OP 2 CLINICAL VALIDITY AND RELIABILITY OF GERDQ-M AND QOLRAD-M** 34
Sangeta Vadivelu, Ong Ean Wah, Norhaliza Hassan, Wong Mung Seong, Syed Hassan Syed Abdul Aziz, Kueh Yee Cheng, Lee Yeong Yeh
 School of Medical Sciences, Universiti Sains Malaysia, Kota Bahru, Malaysia
- OP 3 USE OF ROCKALL RISK SCORE IN PREDICTING 30-DAYS NON-VARICEAL UPPER GASTROINTESTINAL REBLEEDING** 35
Henry Tan Chor Lip¹, Heah Hsin Tak¹, Sarojah Arulanantham¹, Premaa S², Tan Jih Huei¹
¹General Surgery Department, Hospital Sultan Ismail, Johor Bahru, Johor, Malaysia
²Clinical Research Centre, Hospital Sultanah Aminah, Johor Bahru, Johor, Malaysia
- OP 4 CHARACTERISATION OF GENOMIC MUTATIONS IN PROXIMAL AND DISTAL COLORECTAL CANCER PATIENTS** 36
Ryia Illani Mohd Yunos¹, Nurul Syakima Ab Mutalib¹, Sazuita Saidin¹, Norshahidah Nadzir¹, Zuraini Abd Razak¹, Chow Yock Ping¹, Isa Md Rose², Norfilza Mohd Mokhtar^{1,3}, Raja Affendi Raja Ali^{1,4}, Rahman Jamal¹
¹UKM Medical Molecular Biology Institute (UMBI), Kuala Lumpur, Malaysia
²Department of Pathology
³Department of Physiology
⁴Gastroenterology Unit, Faculty of Medicine, Universiti Kebangsaan Malaysia, Kuala Lumpur, Malaysia
- OP 5 THE UTILITY OF FAECAL CALPROTECTIN IN DETERMINING DISEASE ACTIVITY INDEX IN PATIENTS WITH INFLAMMATORY BOWEL DISEASE AT UKM MEDICAL CENTRE** 37
WZA W Abdullah¹, S Mahalinggam¹, S Palaniappan¹, S A Shah², R Abdul Rani¹, C S Ngiu¹, Norfilza Mohd Mokhtar³, R A Raja Ali^{1,3}
¹Gastroenterology Unit, Department of Health and Statistic
²UKM Medical Molecular Biology Institute (UMBI), Kuala Lumpur, Malaysia
³National University of Malaysia Medical Centre, Kuala Lumpur, Malaysia
- OP 6 CORRELATION OF IFN- Γ , IL-6, IL-17A AND IL-17F SERUM LEVELS WITH CLINICAL ASSESSMENT OF DISEASE ACTIVITY IN PATIENTS WITH CROHN'S DISEASE** 37
Nazri Mustaffa¹, Chung Yeng Looi², Ida Hilmi², Khean Lee Goh², Won Fen Wong²
¹Universiti Sains Malaysia, Kubang Kerian, Kelantan, Malaysia
²University of Malaya, Kuala Lumpur, Malaysia

SILYMARIN FOR THE TREATMENT OF NON-ALCOHOLIC STEATOHEPATITIS: INTERIM ANALYSIS OF A RANDOMIZED, DOUBLE-BLIND, PLACEBO-CONTROLLED TRIAL

Wah-Kheong Chan¹, Nik Raihan Nik Mustapha², Sanjiv Mahadeva¹

¹Department of Medicine, Faculty of Medicine, University of Malaya, Kuala Lumpur, Malaysia

²Department of Pathology, Hospital Sultanah Bahiyah, Alor Setar, Kedah, Malaysia

Background

Silymarin, derived from the milk thistle plant, *Silybum marianum*, has been used as a herbal remedy for diseases of the liver.

Methodology

This is a randomized, double-blind, placebo-controlled study of silymarin 700 mg t.i.d. for the treatment of non-alcoholic steatohepatitis (NASH). All included patients had biopsy-proven NASH, were given lifestyle advice, and received either silymarin or placebo for 48 weeks. A repeat liver biopsy was performed at the end of the study. Histology was reported using the NASH Clinical Research Network scoring system.

Results

A total of 64 patients completed the study at the time of this interim analysis. Mean age was 50.2 ± 11.4 years and consisted of 43.8% males. The baseline characteristics were comparable between the silymarin (n = 30) and placebo (n = 34) groups. Significantly more patients in the silymarin group experienced NASH resolution (defined as NAS <3) compared to the placebo group (13.3% vs. 0%, p=0.043). There was also a significant decrease in the fibrosis stage in the silymarin group (Δ = -0.367, p=0.019). This was not observed in the placebo group (Δ = +0.147, p=0.282). A significantly higher percentage of patients in the silymarin group had improvement in fibrosis stage compared to the placebo group (36.7% vs. 14.7%, p=0.043). In addition, four patients in the placebo group developed cirrhosis while none of the patients in the silymarin group did.

Conclusion

A significantly higher percentage of patients experienced NASH resolution and improvement in fibrosis stage after 48 weeks of treatment with silymarin compared to placebo. These preliminary findings should be confirmed by completion of the study and by further studies with a larger number of patients.

CLINICAL VALIDITY AND RELIABILITY OF GERDQ-M AND QOLRAD-M

Sangeta Vadivelu, Ong Ean Wah, Norhaliza Hassan, Wong Mung Seong,
Syed Hassan Syed Abdul Aziz, Kueh Yee Cheng, Lee Yeong Yeh

School of Medical Sciences, Universiti Sains Malaysia, Kota Bharu, Malaysia

Background

Gastroesophageal reflux disease (GERD) is rising in incidence but few data exist on its quality of life among populations in SE Asia. We aimed to test validity and reliability of Malay-translations of GERDQ-M and QOLRAD-M for future studies.

Methods

Internal consistency (Cronbach-alpha) and test-retest reliability (intra-class correlation/ICC) for GERDQ-M and QOLRAD-M were determined in 100 participants. Sequential participants with suspected GERD underwent upper endoscopy, 24-h pH studies and GERDQ-M, QOLRAD-M and SF-36-M were administered. GERDQ-M score ≥ 8 was diagnostic of GERD. Acid exposure was defined as DeMeester score ≥ 14.72 . P < 0.05 was significant.

Results

For GERDQ-M and QOLRAD-M respectively, Cronbach-alpha was 0.78 and 0.95, and ICC was 0.97 and 0.99. 94 (mean age 48.1, male 45.3%, GERD-M ≥ 8 37.2%) participants were enrolled. GERDQ-M ≥ 8 vs. < 8 were more likely to have erosive esophagitis (EE) (P<0.001), hiatus hernia (P=0.03) and increased acid exposure (P=0.01). Total mean scores of QOLRAD-M and SF-36-M were correlated (R=0.34, P<0.001). All five QOLRAD domains (emotional-distress, sleep-disturbance, food/drink problems, physical/social-function and vitality) were impaired with GERDQ-M ≥ 8 vs. < 8 (all P<0.001), EE vs. no EE (all P < 0.05) and DeMeester ≥ 14.72 vs. < 14.72 (all P < 0.001). For SF-36-M, two-domains (personal-problems and energy) were impaired with GERDQ-M ≥ 8 vs. < 8 (both P \leq 0.004), none in EE vs. no EE, and three-domains (personal-problems, emotional well-being and energy) with DeMeester ≥ 14.72 vs. < 14.72 (all P < 0.04).

Conclusion

GERDQ-M and QOLRAD-M are clinically valid and reliable.

USE OF ROCKALL RISK SCORE IN PREDICTING 30-DAYS NON-VARICEAL UPPER GASTROINTESTINAL REBLEEDING

Henry Tan Chor Lip¹, Heah Hsin Tak¹, Sarojah Arulanantham¹, Premaa S², Tan Jih Huei¹

¹General Surgery Department, Hospital Sultan Ismail, Johor Bahru, Johor, Malaysia

²Clinical Research Centre, Hospital Sultanah Aminah, Johor Bahru, Johor, Malaysia

Objective

Upper Gastrointestinal Bleeding(UGIB) is a common emergency with mortality of 14%. The purpose of this study is to determine the usefulness of the Rockall Score(RS) in predicting outcomes of 30 days rebleeding and mortality.

Methodology

This is a 6 year retrospective cohort study of all emergency endoscopy performed in Hospital Sultan Ismail from January 2009 to October 2014 for indications of UGIB. RS were calculated and outcomes of 30 days rebleeding, mortality and need for surgery were recorded. Calibration was done using the Goodness-of-fit tests and discriminative ability of RS scoring system was reflected by area under receiver operating curve(AUROC).

Results

1323 patients were included with a male preponderance of 64%(847) and mean age of 57.9 years . The overall rates of rebleeding were 11.2%(148), mortality 8.7%(115) and surgery 2%(26). Low AUROC values of rebleeding(0.63), mortality(0.58) and surgery(0.67) showed poor discriminative ability of RS. The Goodness-of-fit test also revealed that RS were poorly calibrated in outcomes of rebleeding($p < 0.001$), mortality($p = 0.001$) and surgery($p = 0.038$). Patients with high risk(score ≥ 8) displayed highest rebleeding and mortality rates of 20% respectively in comparison to the moderate(score 3-7) and low(score ≤ 2) risks groups and translates to an odds ratio of 4.02(95% CI: 1.51, 10.66) at rebleeding.

Discussion

We had similar results with NICE 2012 guidelines for management of UGIB that RS has a poor discriminative ability. However, RS was able to classify patients into high risk for rebleeding in our population which was seen in Rockall's landmark study.

Conclusion

Rockall risk score is poorly calibrated and has a poor discriminative ability for rebleeding and mortality in patients with non-variceal UGIB.

CHARACTERISATION OF GENOMIC MUTATIONS IN PROXIMAL AND DISTAL COLORECTAL CANCER PATIENTS

Ryia Illani Mohd Yunos¹, Nurul Syakima Ab Mutalib¹, Sazuita Saidin¹, Norshahidah Nadzir¹,
Zuraini Abd Razak¹, Chow Yock Ping¹, Isa Md Rose², Norfilza Mohd Mokhtar^{1,3},
Raja Affendi Raja Ali^{1,4}, Rahman Jamal¹

¹UKM Medical Molecular Biology Institute (UMBI), Kuala Lumpur, Malaysia

²Department of Pathology

³Department of Physiology

⁴Gastroenterology Unit, Faculty of Medicine, Universiti Kebangsaan Malaysia, Kuala Lumpur, Malaysia

Background and objectives

Colorectal cancer (CRC) is the commonest cancer for men in Malaysia and majority of patients presented with advanced disease at diagnosis in particular proximal CRC. Little is known about the relationship between the genomic mutations, cellular pathways, anatomical location of tumour and prognostication among CRC patients. The objectives: To determine somatic single nucleotide variants and mutations in proximal and distal CRCs and to link with tumour cellular pathway.

Methods

By using Ion Proton platform, the whole exome sequencing on DNA from 10 paired of normal and CRC samples were performed. The sequencing results were analysed by employing Ion Torrent Software and the variants were annotated using ANNOVAR and validated via Sanger Sequencing.

Results

The commonly found mutations in CRC are KRAS, APC, TP53 and ATM. APC was the most frequently altered genes in both proximal and distal CRCs. KRAS and ATM genes were exclusively altered in proximal CRC with frequency of 60% and 40% respectively and TP53 mutations did not show any CRC anatomical predominant. There are 8 novel and recurrent variants for proximal CRC and 1 for distal CRC. Wnt signalling pathway is the most frequently altered pathway in both proximal and distal CRCs whereas TGF- β and PI3K signaling pathways were predominantly altered in the proximal CRC. Four potential druggable alterations BCOR, C9orf50, KRAS, and PLIN3 were identified in the proximal CRC and one recurrent variants in CFAP74 gene in distal CRC.

Conclusions

The APC mutation is frequently altered gene in both proximal and distal CRCs. KRAS and ATM mutations along with TGF- β and PI3K signaling pathway alterations were exclusively occurred in patients with proximal CRCs that potentially responsible for the poor prognosis. Potential druggable mutations in proximal CRCs such as BCOR, C9orf50, KRAS, and PLIN3 have been identified with the hope to improve prognosis among Malaysian patients with CRC in the future.

THE UTILITY OF FAECAL CALPROTECTIN IN DETERMINING DISEASE ACTIVITY INDEX IN PATIENTS WITH INFLAMMATORY BOWEL DISEASE AT UKM MEDICAL CENTRE

WZA W Abdullah¹, S Mahalinggam¹, S Palaniappan¹, S A Shah², R Abdul Rani¹, C S Ngiu¹,
Norfilza Mohd Mokhtar³, R A Raja Ali^{1,3},

¹Gastroenterology Unit, Department of Health and Statistic

²UKM Medical Molecular Biology Institute (UMBI), Kuala Lumpur, Malaysia

³National University of Malaysia Medical Centre, Kuala Lumpur, Malaysia

Objective

To determine the sensitivity and specificity of fecal calprotectin test with endoscopic activity index in IBD patients and to determine the correlation of non invasive biomarker to disease activity.

Methodology

A prospective cross-sectional study of IBD patients from August 2014 till February 2015 was performed. Socio-demographic data, Clinical Disease Activity [Harvey Bradshaw Index for Crohn's disease (CD), Lichtiger Index for Ulcerative colitis (UC)] were taken. Blood were sent for CRP, WBC, Hemoglobin and Platelet. Morning stool sample was taken for fecal calprotectin test. Endoscopic scoring was obtained using Simple Endoscopic Score for Crohn's Disease (SES-CD) and Rachmilewitz Endoscopic Index.

Results

35 patients [18 (51.4%) CD, 17 (48.6%) UC] were recruited. Endoscopic Activity index correlated closest with fecal calprotectin ($r=0.739$), followed by CRP ($r=0.446$) and platelet ($r=0.428$). Fecal calprotectin could significantly discriminate inactive from mild disease [47(35.5-64) vs 127(58-147) ug/g, $p=0.028$]. Significant different of fecal calprotectin level between disease severity groups were seen in both CD [inactive 39.5(33.7-49), mild 127 (88-146), moderate 183 (106-300) and severe 300 (179-300) ug/g, $p=0.019$] and UC [inactive 53 (47-75), mild 98 (67-129), moderate 156 (136-239) and severe 196 (169-248) ug/g, $p=0.034$]. Cutoff value of ≥ 105 ug/g for calprotectin had the best sensitivity and specificity (84% and 100% respectively) of determining inactive and active disease.

Conclusion

Fecal calprotectin correlated closest with endoscopic disease activity in IBD patients compared to other routine biomarkers.

CORRELATION OF IFN- γ , IL-6, IL-17A AND IL-17F SERUM LEVELS WITH CLINICAL ASSESSMENT OF DISEASE ACTIVITY IN PATIENTS WITH CROHN'S DISEASE

Nazri Mustaffa¹, Chung Yeng Looi², Ida Hilmi², Khean Lee Goh², Won Fen Wong²

¹Universiti Sains Malaysia, Kubang Kerian, Kelantan, Malaysia

²University of Malaya, Kuala Lumpur, Malaysia

Objectives

Th17 cells have been implicated in the pathogenesis of inflammatory bowel disease. In mouse models the cytokines IL-17A and IL-17F produced by these cells have been demonstrated to have opposite roles; IL-17A protective whilst IL-17F was pathogenic in dextran sulfate sodium-induced mouse models of acute colitis. Not much is known regarding the relationship between IL-17A and IL-17F serum levels with clinical parameters of disease activity in human Crohn's disease (CD) subjects. We thus sought to elucidate this relationship in our cohort of patients with CD.

Methodology

Blood samples were obtained from subjects attending the Gastroenterology Clinic, University Malaya Medical Centre. Clinical parameters were recorded, and disease activity was assessed using the Harvey-Bradshaw Index. Subject's sera were then analysed via ELISA for the Th1 and Th17-related cytokines IFN- γ and IL-6, as well as for IL-17A and IL-17F levels. Control subjects were those who had undergone endoscopic examination for suspected gastrointestinal disease, but with no abnormality found on subsequent follow-up.

Results

A total of 31 subjects were recruited (22 with CD and 9 healthy controls). For subjects with CD IFN- γ , IL-6, and IL-17F but not IL-17A levels were shown to significantly correlate with disease activity (Pearson r and p -value 0.62, <0.01 ; 0.43, <0.05 ; -0.03, ns; 0.70, <0.01 respectively).

Conclusion

In our CD patients IL-17A levels were not significantly related to disease activity, whilst there was a positive correlation for IFN- γ , IL-6 and IL-17F.

POSTER PRESENTATIONS

- PP 1** **EPIDEMIOLOGY AND RISK FACTORS FOR HEPATITIS C VIRUS INFECTION DETECTED IN HOSPITAL TUANKU FAUZIAH, KANGAR, PERLIS IN 2014** **46**
S Tang, N Rizal, Alia F, A Toong, K K Sia
 Gastroenterology Unit, Medical Department, Hospital Tuanku Fauziah, Kangar, Perlis, Malaysia
- PP 2** **RECTAL FOREIGN OBJECTS, DOES THE CARE ENDS AFTER REMOVAL? - A CASE REPORT AND LITERATURE REVIEW** **46**
Henry Tan Chor Lip, Seniyah Md Sikin, Tan Jih Huei
 General Surgery Department, Hospital Sultan Ismail, Johor Bahru, Johor, Malaysia
- PP 3** **ABDOMINAL ACTINOMYCOSIS: A FORGOTTEN DISEASE** **47**
B H Ooi¹, M R Hassan¹, Z Zalwani¹, M S Firdaus¹, C H Loo², K K Kiew¹
¹Department of Internal Medicine, Hospital Sultanah Bahiyah, Alor Setar, Kedah, Malaysia
²Department of Internal Medicine, Hospital Sultan Abdul Halim, Sungai Petani, Kedah, Malaysia
- PP 4** **BLEEDING ILEAL LIPOMA: AN EXTREMELY RARE PRESENTATION OF ANEMIA IN ADULTS** **47**
B H Ooi¹, M R Hassan¹, Z Zalwani¹, M S Firdaus¹, C H Loo², K K Kiew¹
¹Department of Internal Medicine, Hospital Sultanah Bahiyah, Alor Setar, Kedah, Malaysia
²Department of Internal Medicine, Hospital Sultan Abdul Halim, Sungai Petani, Kedah, Malaysia
- PP 5** **FIGHTER OR GENOMICS? SURVIVING A DECADE OF LIVER CANCER CONSERVATIVELY** **48**
B H Ooi¹, M R Hassan¹, Z Zalwani¹, M S Firdaus¹, C H Loo², K K Kiew¹
¹Department of Internal Medicine, Hospital Sultanah Bahiyah, Alor Setar, Kedah, Malaysia
²Department of Internal Medicine, Hospital Sultan Abdul Halim, Sungai Petani, Kedah, Malaysia
- PP 6** **EOSINOPHILIC ESOPHAGITIS AND NON-EROSIVE REFLUX DISEASE IN AN ENDOSCOPED ADULT MALAYSIAN POPULATION WITH REFLUX SYMPTOMS** **48**
Noorlina Nordin¹, NorAizal Che Hamzah², Sharifah Emilia¹, Ong Ean Wah¹, Norhaliza Hassan¹, Mung Seong Wong¹, Syed Hassan Syed Abdul Aziz¹, Hoi Poh Tee³, Yeong Yeh Lee¹
¹School of Medical Sciences, Universiti Sains Malaysia, Kota Bahru, Kelantan, Malaysia
²Hospital Pakar KPJ Pasir Gudang, Johor Bahru, Johor, Malaysia
³Hospital Tengku Ampuan Afzan, Kuantan, Pahang, Malaysia
- PP 7** **SIGNIFICANT RISK OF LIFE THREATENING INFECTIONS IN ELDERLY PATIENTS WITH INFLAMMATORY BOWEL DISEASE RECEIVING ANTI-TNF THERAPY** **49**
Ahmad Najib Azmi^{1,3}, Way-Seah Lee², Ruey Terng Ng², Sik-Yong Ong², Sanjiv Mahadeva¹, Khean-Lee Goh¹, Ida Hilmi¹
¹Department of Medicine, University of Malaya, Kuala Lumpur, Malaysia
²Department of Paediatrics, University of Malaya, Kuala Lumpur, Malaysia
³Department of Medicine, University Sains Islam Malaysia, Kuala Lumpur, Malaysia
- PP 8** **CHANGES OF DISTRIBUTION OF HEPATITIS C GENOTYPE IN PAHANG, MALAYSIA IN THE PAST DECADE: IS THERE ANY?** **50**
M H Hasmoni¹, K A Jaafar¹, A Che Aun², H P Tee²
¹International Islamic University Malaysia, Kuantan, Pahang, Malaysia
²Hospital Tengku Ampuan Afzan, Kuantan, Pahang, Malaysia
- PP 9** **EFFICACY AND SAFETY OF PROPHYLACTIC SUPPOSITORY DICLOFENAC IN PREVENTION OF POST-ERCP PANCREATITIS (PEP) IN HIGH RISK PATIENTS IN SELAYANG HOSPITAL** **51**
H F Khoo¹, T S Lee², X Y Lim¹, Nur Farhana Mohd Noor¹, K M Voon¹, P S Chua¹, Siti Hajar Abdul Kadir¹, Najihah Mohd Termizi¹, Krishnan a/l Raman³
¹Pharmacy Department Selayang Hospital, Selangor, Malaysia
²Hepato-Gastroenterology Department Selayang Hospital, Selangor, Malaysia
³Hepatobiliary Department Selayang Hospital, Selangor, Malaysia

POSTER PRESENTATIONS

- PP 10 CASE REPORT: FAMILIAL ADENOMATOUS POLYPOSIS FUNDAL GASTRIC CANCER WITH MULTIPLE LIVER METASTASIS** 52
Tee Teong Jin¹, Nimalarajan Kanagarajan², Joharuddin Bin Md Kasim³
¹Medical Department, Nilai Medical Centre, Nilai, Negeri Sembilan, Malaysia
²Surgical Department, Nilai Medical Centre, Nilai, Negeri Sembilan, Malaysia
³Radiology Department, Nilai Medical Centre, Nilai, Negeri Sembilan, Malaysia
- PP 11 CASE REPORT: PRIMARY DIFFUSE LARGE B CELL LYMPHOMA OF THE CAECUM AND ASCENDING COLON** 52
Tee Teong Jin¹, Nimalarajan Kanagarajan²
¹Medical Department, Nilai Medical Centre, Nilai, Negeri Sembilan, Malaysia
²Surgical Department, Nilai Medical Centre, Nilai, Negeri Sembilan, Malaysia
- PP 12 MONO OR DUAL THERAPY, ARE WE FOLLOWING THE STANDARD? AN AUDIT OF UPPER GASTROINTESTINAL BLEEDING** 53
Henry Tan Chor Lip¹, Nur Fitriyani Afiqah², Tan Jih Huei¹
¹General Surgery Department, Hospital Sultan Ismail, Johor Bahru, Johor, Malaysia
²Newcastle University Medicine Malaysia, Johor Bahru, Johor, Malaysia
- PP 13 SPYGLASS® CHOLANGIOSCOPY FOR LARGE CHOLEDOCHOLITHIASIS WITH A REUSED SPYSCOPE: A SINGLE-CENTRE EXPERIENCE (CASE SERIES)** 53
Shiau-Hooi Ho¹, Sanjiv Mahadeva¹, Sook-Hui Chaw², Pui-San Loh², Khean-Lee Goh¹
¹Department of Medicine, University of Malaya, Kuala Lumpur, Malaysia
²Department of Anaesthesiology, University of Malaya, Kuala Lumpur, Malaysia
- PP 14 HIGH DOSE AMOXICILLIN-DEXLANSOPRAZOLE DUAL THERAPY IS A PROMISING SECOND LINE RESCUE THERAPY FOR *H. PYLORI* INFECTION** 54
Alex Hwong-Ruey Leow¹, Ahmad Najib Azmi², Khean Lee Goh¹
¹Division of Gastroenterology and Hepatology, Department of Medicine, Faculty of Medicine, University of Malaya, Kuala Lumpur, Malaysia
²Faculty of Medicine and Health Sciences, Universiti Sains Islam Malaysia, Kuala Lumpur, Malaysia
- PP 15 A REVIEW OF CAPSULE ENDOSCOPY STUDIES IN HOSPITAL AMPANG** 54
Sudarshan Krishnamurthi, Sattian Kollanthavelu, Rosaida Md Said
 Hospital Ampang, Selangor, Malaysia
- PP 16 SANDORICUM KOETJAPE (SANTOL OR COTTONFRUIT) - INDUCED SIGMOID COLON PERFORATION** 55
Dyg Zahratul Hamrak, Norliana Jaafar, Annisa Zainal Mokhtar, Rashide Yaacob
 Department of General Surgery, Hospital Sultan Abdul Halim, Sungai Petani, Kedah, Malaysia
- PP 17 COLLAGENOUS COLITIS: A CASE REPORT** 55
Muhammad Ilham Abdul Hafidz¹, Thevaraajan Jayaraman¹, Effat Omar², Annamalai Chandramouli¹
¹Department of Internal Medicine, Faculty of Medicine, Universiti Teknologi MARA (UiTM), Selangor, Malaysia
²Department of Pathology, Faculty of Medicine, Universiti Teknologi MARA (UiTM), Selangor, Malaysia
- PP 18 OPTIMISING FIRST LINE *H. PYLORI* ERADICATION THERAPY: PROLONGING TREATMENT OR ADD-ON THERAPY, WHICH IS BETTER?** 56
Alex Hwong-Ruey Leow¹, Ahmad Najib Azmi², Khean Lee Goh¹
¹Division of Gastroenterology and Hepatology, Department of Medicine, Faculty of Medicine, University of Malaya, Kuala Lumpur, Malaysia
²Faculty of Medicine and Health Sciences, Universiti Sains Islam Malaysia, Kuala Lumpur, Malaysia
- PP 19 REVIEW OF UPPER GASTROINTESTINAL ENDOSCOPY PERFORMED IN UITM IN 2014** 56
Thevaraajan Jayaraman, Rafiz Abdul Rani, Mohd Ilham Abdul Hafidz, Annamalai Chandramouli
 Gastroenterology Unit, Department of Internal Medicine, Faculty of Medicine, Universiti Teknologi MARA (UiTM), Selangor, Malaysia

POSTER PRESENTATIONS

- PP 20** **ERCP CANNULATION SUCCESS RATE IN A TERTIARY HOSPITAL IN EAST COAST PENINSULAR MALAYSIA: BENCHMARKING WITH STANDARDS** **57**
S K Kutty¹, M H Hasmoni¹, K A Jaafar¹, A Che Aun², H P Tee²
¹International Islamic University Malaysia, Kuantan, Pahang, Malaysia
²Hospital Tengku Ampuan Afzan, Kuantan, Pahang, Malaysia
- PP 21** **HAEMATEMESIS: A RARE MANIFESTATION OF DISSECTING THORACIC AORTIC ANEURYSM** **57**
Dyg Zahratul Hamrak, Norliana Jaafar, Annisa Zainal Mokhtar, Rashide Yaacob
 Department of General Surgery, Hospital Sultan Abdul Halim, Sungai Petani, Kedah, Malaysia
- PP 22** **LIVER FIBROSIS EPIDEMIOLOGY REVISITED USING SOFTWARE COMBINED BIOMARKER: PROOF OF CONCEPT USING 1,081,658 CENTRALIZED FIBROTEST (FT) PRESCRIPTIONS** **58**
*Thierry Poynard^{*1, 2, 3} on behalf of FibroFRANCE, Olivier Deckmyn⁴, Joe Sebastian⁵, Mona Munteanu⁴, Yen Ngo⁴, Fabienne Drane⁴, Janet Queen⁵, Jean Marie Castille⁴*
¹Groupe Hospitalier Pitie Salpetriere APHP
²UPMC
³INSERM UMR S938
⁴BioPredictive, Paris, France
⁵Labcorp, Burlington, United States of America
- PP 23** **DIRECT COMPARISONS OF FIBROTEST, APRI, FIB-4, AND TRANSIENT ELASTOGRAPHY (TE) FOR THE DIAGNOSIS OF CIRRHOSIS AND FIBROSIS, IN PATIENTS WITH CHRONIC HEPATITIS C (CHC) AND B (CHB) USING INTENTION TO DIAGNOSE AND BAYESIAN METHODS. A SYSTEMATIC REVIEW** **59**
*Marion Houot¹, Yen Ngo¹, Mona Munteanu¹, Sebastien Marque², Thierry Poynard^{*3}*
¹BioPredictive
²Capionis
³APHP, Paris, France
- PP 24** **CASE REPORT : A CASE OF DISSEMINATED TUBERCULOSIS WITH SUBACUTE INTESTINAL OBSTRUCTION SECONDARY TO ILEAL STRICTURE** **60**
James Emmanuel¹, Nagaraj Sriram¹, Mandeep Singh¹, Raman Muthukaruppan¹, Jayaram Menon¹, Kunji Kannan Sivaraman Kannan²
¹Medical Department, Hospital Queen Elizabeth, Kota Kinabalu, Sabah, Malaysia
²Department of Respiratory, Hospital Queen Elizabeth, Kota Kinabalu, Sabah, Malaysia
- PP 25** **AWARENESS AND PERCEPTIONS OF COLORECTAL CANCER AND SCREENING AMONG THE POPULATION IN SABAH** **61**
James Emmanuel¹, Ruben Raj¹, Raman Muthukaruppan¹, Jayaram Menon¹, Chin Suliong², Naing Oo Tha², Khin Ye Myint²
¹Department of Medicine, Hospital Queen Elizabeth, Kota Kinabalu, Sabah, Malaysia
²School of Medicine, Universiti Malaysia Sabah, Kota Kinabalu, Sabah, Malaysia
- PP 26** **IS CONTROLLED ATTENUATION PARAMETER WITH THE XL PROBE MORE ACCURATE THAN THE M PROBE FOR ESTIMATION OF HEPATIC STEATOSIS IN PATIENTS WITH NON-ALCOHOLIC FATTY LIVER DISEASE?** **62**
Wah-Kheong Chan¹, Nik Raihan Nik Mustapha², Sanjiv Mahadeva¹
¹Department of Medicine, Faculty of Medicine, University of Malaya, Kuala Lumpur, Malaysia
²Department of Pathology, Hospital Sultanah Bahiyah, Alor Setar, Kedah, Malaysia
- PP 27** **CROHN'S DISEASE PRESENTED WITH INTESTINAL OBSTRUCTION** **62**
Dyg Zahratul Hamrak, Annisa Zainal Mokhtar, Su Kim Peng, Rashide Yaacob
 Department of General Surgery, Hospital Sultan Abdul Halim, Sungai Petani, Kedah, Malaysia

POSTER PRESENTATIONS

- PP 28 MESENCHYMAL STEM CELL THERAPY FOR ADVANCED LIVER CIRRHOSIS: A CASE REPORT** **63**
Ruveena Rajaram¹, Baskar Subramni², B J Jeet Abdullah¹, Sanjiv Mahadeva¹
¹Pusat Perubatan Universiti Malaya, Kuala Lumpur, Malaysia
²Nichi-Asia Life Science Sdn Bhd, Petaling Jaya, Selangor, Malaysia
- PP 29 TITLE: MODIFIED WHIPPLE PANCREATODUODENECTOMY: HOW SAFE IS THIS PROCEDURE IN MALAYSIA?** **63**
Bong Jan Jin
 Sunway Medical Centre, Petaling Jaya, Selangor, Malaysia
- PP 30 LAPAROSCOPIC LIVER RESECTION IN MALAYSIA** **64**
Bong Jan Jin
 Hospital Universiti Kebangsaan Malaysia, Kuala Lumpur, Malaysia
 Sunway Medical Centre, Petaling Jaya, Selangor, Malaysia
- PP 31 DIAGNOSTIC UTILITY OF ENDOSCOPIC ULTRASOUND-FINE NEEDLE ASPIRATION FOR PANCREATIC CARCINOMA – A RETROSPECTIVE STUDY IN UNIVERSITY MALAYA MEDICAL CENTRE** **64**
J E Tai¹, W K Chan^{1,3}, Rajesh Kumar^{1,2}, B K Yoong¹, K L Goh², I Hilmi²
¹University of Malaya, Kuala Lumpur, Malaysia
²University Putra Malaysia, Selangor, Malaysia
³University of Sydney, New South Wales, Australia
- PP 32 A RARE CASE OF CONGENITAL MESSENTERIC DEFECT – A CASE REPORT** **65**
Raveen K, Theebanraja R, Rudyanto, Balasingh D
 Hospital Tuanku Ampuan Najihah, Kuala Pilah, Negeri Sembilan, Malaysia
- PP 33 THE MYSTERY OF THE WHITE LESIONS – A CASE REPORT** **65**
M F Limun¹, R Abdul Rani², C S Ngiu¹, R A Raja Ali¹
¹National University of Malaysia (UKM), Kuala Lumpur, Malaysia
²Universiti Teknologi MARA (UITM), Selangor, Malaysia
- PP 34 AMOEBIC COLITIS; ANOTHER GREAT MIMICKER? – A CASE REPORT** **66**
R Abdul Rani¹, M F Limun², C S Ngiu², R A Raja Ali²
¹Universiti Teknologi MARA (UITM), Selangor, Malaysia
²National University of Malaysia (UKM), Kuala Lumpur, Malaysia
- PP 35 IDENTIFICATION OF MOLECULAR CHARACTERIZATION OF SOMATIC MUTATIONS USING TARGETING SEQUENCING IN DUKES' B AND C COLORECTAL CANCER PATIENTS** **67**
Shafina Nadiawati Abdul¹, Nurul Syakima Ab Mutalib¹, Ismail Sagap³, Isa Mohamed Rose⁴, Rahman Jamal¹, Raja Affendi Raja Ali^{1,5}, Norfilza Mohd Mokhtar^{1,2}
¹UKM Medical Molecular Biology Institute, ²Department of Physiology, ³Surgery, ⁴Pathology, and ⁵Gastroenterology Unit, Faculty of Medicine, Universiti Kebangsaan Malaysia, Kuala Lumpur, Malaysia
- PP 36 AN ASSESSMENT OF QUALITY OF LIFE IN RELATION TO THE DISEASE ACTIVITY INDEX AMONG PATIENTS WITH IBD AT UKM MEDICAL CENTRE** **68**
S Mahalinggam¹, W Z A W Abdullah¹, S Palaniappan¹, Shamsul A S², R Abdul Rani¹, C S Ngiu¹, Norfilza Mohd Mokhtar³, R A Raja Ali^{1,3}
¹Gastroenterology Unit, Universiti Kebangsaan Malaysia Medical Centre, Kuala Lumpur, Malaysia
²Department of Health and Statistics, Universiti Kebangsaan Malaysia Medical Centre, Kuala Lumpur, Malaysia
³UKM Medical Biology Institute, Universiti Kebangsaan Malaysia Medical Centre, Kuala Lumpur, Malaysia

POSTER PRESENTATIONS

- PP 37 CLINICO-PATHOLOGICAL CHARACTERISTICS OF PATIENTS WHO WERE POSITIVE FOR M2-PK TEST IN THEIR STOOL, FOCUSED LOOK INTO UKM COHORT** 69
Hajhamad M¹, Raja Affendi Raja Ali², Zairul Azwan¹, Nur Afdzillah Rahman¹, F J Ruhi¹, Sagap I¹
¹Colorectal Surgery Unit, Department of Surgery, Universiti Kebangsaan Malaysia Medical Centre, Kuala Lumpur, Malaysia
²Gastroenterology Unit, Department of Medicine, Universiti Kebangsaan Malaysia Medical Centre, Kuala Lumpur, Malaysia
- PP 38 CASE REPORT: SUCCESSFUL CONSERVATIVE MANAGEMENT OF PANCREATICO-COLONIC FISTULA FOLLOWING VIDEOSCOPIC ASSISTED RETROPERITONEAL DEBRIDEMENT OF INFECTED PANCREATIC NECROSIS** 70
Hajhamad M¹, Reynu R, Kosai N R, Mustafa M T, Othman H²
¹Minimally Invasive, Upper GI and Bariatric Surgery Unit, Department of Surgery, Department of Medicine, Universiti Kebangsaan Malaysia Medical Centre, Kuala Lumpur, Malaysia
²Hepatobiliary Surgery Unit, Department of Medicine, Universiti Kebangsaan Malaysia Medical Centre, Kuala Lumpur, Malaysia
- PP 39 IMMUNOTHERAPY IN HEPATIC SARCOIDOSIS - A CLINICAL CHALLENGE** 70
Z Q Wong¹, Mahadeva S²
¹University Kebangsaan Malaysia Medical Centre, Kuala Lumpur, Malaysia
²University Malaya Medical Centre, Kuala Lumpur, Malaysia
- PP 40 THE CHANGING EPIDEMIOLOGY OF HEPATITIS C PATIENTS IN THE SARAWAK GENERAL HOSPITAL** 71
V S L Kok¹, F W de Rozario¹, S Y Wong¹, S Y Soon²
¹Sarawak General Hospital, Kuching, Sarawak, Malaysia
²Kuching Specialist Hospital, KPJ, Kuching, Sarawak, Malaysia
- PP 41 CASE REPORT: AN UNCOMMON CAUSE OF CHRONIC ABDOMINAL PAIN** 71
Jasminder Kaur, Mandeep Singh, Raman Muthukaruppan, Jayaram Menon
 Queen Elizabeth Hospital, Sabah, Malaysia
- PP 42 CASE REPORT: RECURRENT ACUTE PANCREATITIS IN A YOUNG LADY** 72
Jasminder Kaur, Mandeep Singh, Raman Muthukaruppan, Jayaram Menon
 Queen Elizabeth Hospital, Sabah, Malaysia
- PP 43 A RETROSPECTIVE ANALYSIS OF COLORECTAL CANCERS DIAGNOSED IN QUEEN ELIZABETH HOSPITAL** 72
Jasminder Kaur, Mandeep Singh, Raman Muthukaruppan, Jayaram Menon
 Queen Elizabeth Hospital, Sabah, Malaysia
- PP 44 A REVIEW OF HEPATOBILIARY TUBERCULOSIS – A SABAH EXPERIENCE** 73
Jasminder Kaur, James Emanuelle, Nerentheran Loganathan, Mandeep Singh, Raman Muthukaruppan, Jayaram Menon
 Queen Elizabeth Hospital, Sabah, Malaysia
- PP 45 EFFECTS OF TYPE D PERSONALITY ON FOLLOW-UP DURATION AND ADHERENCE TO MEDICATIONS AMONG GERD PATIENTS** 73
Kosholah B, Kugan V, Shrinivan G, Jovi C J H, Mahadevan D
 Department of General Surgery, Tuanku Ja'afar Hospital, Seremban, Negeri Sembilan, Malaysia
- PP 46 SCREENING OF FUNCTIONAL CONSTIPATION AMONG STUDENTS IN UNIVERSITI PUTRA MALAYSIA, SERDANG** 74
Ying-Jye L¹, Rosita J¹, J Y Chieng², P Yap², Rajesh P²
¹Department of Nutrition and Dietetics, Faculty of Medicine and Health Sciences, Universiti Putra Malaysia, Selangor, Malaysia
²Department of Medicine, Faculty of Medicine and Health Sciences, Universiti Putra Malaysia, Selangor, Malaysia

POSTER PRESENTATIONS

- PP 47 PREVALENCE OF HELICOBACTER PYLORI INFECTIONS AMONG PATIENTS REFERRED FOR ENDOSCOPY AT HOSPITAL SULTAN ABDUL HALIM** 74
Kirubakaran Ranita¹, Ooi Ching Yee¹, Su Kim Peng², Izhar Nur Amira²
 Hospital Sultan Abdul Halim, Sungai Petani, Malaysia
- PP 48 PROFILE AND OUTCOME OF VARICEAL BLEEDING PATIENTS REFERRED FOR ENDOSCOPY AT HOSPITAL SULTAN ABDUL HALIM** 75
Kirubakaran Ranita, Ooi Ching Yee, Su Kim Peng, Syah Rizal Irwan
 Hospital Sultan Abdul Halim, Sungai Petani, Kedah, Malaysia
- PP 49 AN INCIDENTAL FINDING OF AN EXTRALUMINAL DUODENAL DIVERTICULUM** 75
Thevarajan Jayaraman, Rafiz Abdul Rani, Mohd Ilham Abdul Hafidz, Annamalai Chandramouli
 Gastroenterology Unit, Department of Internal Medicine, Faculty of Medicine, Universiti Teknologi MARA (UiTM), Selangor, Malaysia
- PP 50 INCIDENCE OF UPPER GASTRO-INTESTINAL CANCER IN HOSPITAL TUANKU JA'AFAR, SEREMBAN FROM 2008-2014. A POPULATION BASED TREND ANALYSIS** 76
Mohanraj T¹, A Vijaya Shankar¹, Azrina A B¹, Kandasami P², Mahadevan D Tata¹
¹Hospital Tuanku Ja'afar, Seremban, Negeri Sembilan, Malaysia
²International Medical University, Seremban, Negeri Sembilan, Malaysia
- PP 51 THE PATTERNS OF BLEEDING PEPTIC ULCER DISEASE AND METHODS OF ENDOSCOPIC HAEMOSTASIS: A SINGLE CENTRE EXPERIENCE** 77
S Rosemi, A B Norasiah, J W Aina, M Norhashimah
 Gastroenterology Unit, Department of Medicine, Hospital Raja Perempuan Zainab II, Kota Bharu, Kelantan, Malaysia
- PP 52 FIRST CASE REPORT OF BEEF TAENIASIS FROM SABAH, MALAYSIA** 78
James Emmanuel¹, Nagaraj Sriram¹, Mandeep Singh¹, Raman Muthukaruppan¹, Jayaram Menon¹, Tock H Chua²
¹Department of Medicine, Hospital Queen Elizabeth, Kota Kinabalu, Sabah, Malaysia
²Department of Pathobiology & Medical Diagnostics, Faculty of Medicine and Health Sciences, Universiti Malaysia Sabah, Kota Kinabalu, Sabah, Malaysia
- PP 53 CHRONIC HEPATITIS C TREATMENT - LABUAN HOSPITAL EXPERIENCE** 79
Raman Muthukaruppan¹, Vinoth Rajan², Hema Yamini², Saw Y T²
¹Hospital Queen Elizabeth, Kota Kinabalu, Sabah, Malaysia
²Hospital Labuan, Wilayah Persekutuan Labuan, Malaysia
- PP 54 CASE REPORT: SUPERIOR MESENTRIC ARTERY SYNDROME IN A PATIENT WITH COLORECTAL CANCER** 80
James Emmanuel¹, Lily Lim Hooi Min², Nagaraj Sriram¹, Mandeep Singh¹, Raman Muthukaruppan¹, Wan NajwaZaini Bt Wan Mohamed², Jayaram Menon¹
¹Department of Medicine, Hospital Queen Elizabeth, Kota Kinabalu, Sabah, Malaysia
²Department of Radiology, Hospital Queen Elizabeth, Kota Kinabalu, Sabah, Malaysia
- PP 55 A GASTRIC BEZOAR IN BILLROTH II STOMACH: A CASE REPORT ON SUCCESSFUL ENDOSCOPIC REMOVAL VIA REPEATED FRAGMENTATION AND DISSOLUTION TECHNIQUES NEGATING THE NEED FOR SURGICAL INTERVENTION** 81
J Y Chieng¹, S H Ho², K L Goh²
¹Faculty of Medicine and Health Science, Putra University of Malaysia, Selangor, Malaysia
²Department of Medicine, University of Malaya, Kuala Lumpur, Malaysia
- PP 56 CASE REPORT: A CASE OF VON HIPPEL LINDAU PRESENTING WITH PANCREATIC CYST** 82
James Emmanuel, Nagaraj Sriram, Mandeep Singh, Raman Muthukaruppan, Jayaram Menon
 Medical Department, Hospital Queen Elizabeth, Kota Kinabalu, Sabah, Malaysia

POSTER PRESENTATIONS

- PP 57 CASE REPORT : EUS GUIDED PSEUDOCYST DRAINAGE : A CASE OF PANCREATIC PSEUDOCYST WITH UNDERLYING SMALL CELL NEUROENDOCRINE CARCINOMA OF THE UTERINE CERVIX** 82
James Emmanuel, Nagaraj Sriram, Mandeep Singh, Raman Muthukaruppan, Jayaram Menon
 Medical Department, Hospital Queen Elizabeth, Kota Kinabalu, Sabah, Malaysia
- PP 58 UPPER GASTROINTESTINAL ENDOSCOPIC EVALUATION OF IRON DEFICIENCY ANEMIA IN CHRONIC KIDNEY DISEASE PATIENTS** 83
C K Lee¹, Saravanan A¹, E S Tan¹, L T Gew¹, Jaideep S¹, YY Ngau²
¹Gastroenterology Unit, Medical Department, Hospital Kuala Lumpur, Kuala Lumpur, Malaysia
²Medical Department, Hospital Kuala Lumpur, Kuala Lumpur, Malaysia
- PP 59 COLONOSCOPY EVALUATION OF CHRONIC DIARRHOEA IN DIABETIC PATIENTS** 84
C K Lee¹, Saravanan A¹, E S Tan¹, L T Gew¹, Jaideep S¹, YY Ngau²
¹Gastroenterology Unit, Medical Department, Hospital Kuala Lumpur, Kuala Lumpur, Malaysia
²Medical Department, Hospital Kuala Lumpur, Kuala Lumpur, Malaysia
- PP 60 AUDIT OF UGIE ON ASYMPTOMATIC PATIENT GOING FOR RENAL TRANSPLANT** 84
L T Gew¹, Navanithan R¹, C K Lee¹, E S Tan¹, Jaideep S¹, Saravanan A¹, YY Ngau²
¹Gastroenterology Unit, Medical Department, Hospital Kuala Lumpur, Kuala Lumpur, Malaysia
²Medical Department, Hospital Kuala Lumpur, Kuala Lumpur, Malaysia
- PP 61 OUTCOME OF PATIENTS WITH DERANGED LIVER FUNCTION TEST WITH OR WITHOUT LOSS OF SYNTHETIC FUNCTION OF LIVER IN SEVERE DENGUE** 85
L T Gew¹, C C Tan¹, C K Lee¹, E S Tan¹, Jaideep S¹, Saravanan A¹, YY Ngau²
¹Gastroenterology Unit, Medical Department, Hospital Kuala Lumpur, Kuala Lumpur, Malaysia
²Medical Department, Hospital Kuala Lumpur, Kuala Lumpur, Malaysia
- PP 62 EFFECT OF FIBRIN GLUE IN PREVENTION OF DELAYED BLEEDING POST GASTRIC ENDOSCOPIC SUBMUCOSAL DISSECTION** 86
E S Tan¹, Feng Liu², Hua Wang³
¹Gastroenterology Unit, Medical Department, Hospital Kuala Lumpur, Kuala Lumpur, Malaysia
²Changhai Hospital, Shanghai, China
- PP 63 CHRONIC HEPATITIS C GENOTYPE 1 TREATMENT WITH BOCEPREVIR/ PEGINTERFERON ALFA-2A/RIBAVIRIN: LOCAL SABAH EXPERIENCE** 86
Sriram Nagaraj, Siew Phung Tan, James Emmanuel, Mandeep Singh, Raman Muthukaruppan, Jayaram Menon
 Department of Medicine, Hospital Queen Elizabeth, Kota Kinabalu, Sabah, Malaysia
- PP 64 CASE REPORT: DISTAL ESOPHAGEAL STRICTURE – A RARE PRESENTATION OF A COMMON DISEASE - TUBERCULOSIS** 87
Sriram Nagaraj, James Emmanuel, Mandeep Singh, Raman Muthukaruppan, Jayaram Menon
 Medical Department, Hospital Queen Elizabeth, Kota Kinabalu, Sabah, Malaysia
- PP 65 CASE REPORT : PRIMARY DUODENAL ASPERGILLOSIS – CASE REPORT IN IMMUNOCOMPETENT ADULT** 87
Sriram Nagaraj, James Emmanuel, Mandeep Singh, Raman Muthukaruppan, Jayaram Menon
 Medical Department, Hospital Queen Elizabeth, Kota Kinabalu, Sabah, Malaysia
- PP 66 CASE REPORT: BILIARY ASCARIASIS – CAUSE OF RECURRENT ABDOMINAL PAIN DIAGNOSED WITH ENDOSCOPIC ULTRASOUND** 88
Sriram Nagaraj, James Emmanuel, Mandeep Singh, Raman Muthukaruppan, Jayaram Menon
 Medical Department, Hospital Queen Elizabeth, Kota Kinabalu, Sabah, Malaysia

POSTER PRESENTATIONS

- PP 67 A RETROSPECTIVE, OBSERVATIONAL STUDY ON EFFECT OF PROTON PUMP INHIBITORS ON THE OUTCOME OF PEPTIC ULCER BLEEDING: COMPARISON BETWEEN IV Eesomeprazole AND IV Pantoprazole 88**
Sriram Nagaraj¹, Hui Ling Tay¹, Peter Tok², James Emmanuel¹, Mandeep Singh¹, Raman Muthukaruppan¹, Jayaram Menon¹
¹Medical Department, Hospital Queen Elizabeth, Kota Kinabalu, Sabah, Malaysia
²Clinical Research Centre, Hospital Queen Elizabeth, Kota Kinabalu, Sabah, Malaysia
- PP 68 CHYLOUS ASCITES AS A RARE MANIFESTATION OF CONGESTIVE CARDIAC FAILURE 89**
Ganesh Kasinathan, Mohd Shafiq Rahman, Sirajudeen Rowther
 Department of Internal Medicine, Hospital Segamat, Johor, Malaysia
- PP 69 GASTROINTESTINAL LUMINAL TUBERCULOSIS: 21 CASES COLLECTED IN HOSPITAL QUEEN ELIZABETH IN KOTA KINABALU, SABAH 89**
James Emmanuel¹, Thamron Keowmani², Grace Tay Hui Ling¹, Nagaraj Sriram¹, Mandeep Singh¹, Raman Muthukaruppan¹, Jayaram Menon¹
¹Department of Medicine, Queen Elizabeth Hospital, Kota Kinabalu, Sabah, Malaysia
²Clinical Research Centre, Queen Elizabeth Hospital, Kota Kinabalu, Sabah, Malaysia
- PP 70 OUTCOME OF THE COLORECTAL CANCER SURVEILLANCE COLONOSCOPY 90**
Saravanan A¹, E S Tan¹, Jaideep S¹, C K Lee¹, L T Gew¹, Y Y Ngau²
¹Gastroenterology Unit, Medical Department, Hospital Kuala Lumpur, Kuala Lumpur, Malaysia
²Medical Department, Hospital Kuala Lumpur, Kuala Lumpur, Malaysia

EPIDEMIOLOGY AND RISK FACTORS FOR HEPATITIS C VIRUS INFECTION DETECTED IN HOSPITAL TUANKU FAUZIAH, KANGAR, PERLIS IN 2014

S Tang, N Rizal, Alia F, A Toong, K K Sia

Gastroenterology Unit, Medical Department, Hospital Tuanku Fauziah, Kangar, Perlis, Malaysia

Objectives

To study the epidemiology and risk factors for hepatitis C virus infection in those who tested positive for anti-HCV in Hospital Tuanku Fauziah in the year 2014.

Methods

This is a retrospective study of individuals who tested positive for anti-HCV in 2014. Positive cases were traced from the laboratory computer system. Epidemiological data was obtained from laboratory request forms and patient case notes. Data was then analyzed.

Results

A total of 204 individuals tested positive for anti-HCV in 2014 which is 6.3% of the total number of screenings. 185 (91%) individuals were male, 18 (9%) were female. The age in our sample ranged from 19 to 82 years with the mean age being 40 years. In the males, the largest number of cases came from the age 30 -39 years group while in females the largest number is from the 20-29 years age group. Malays made up the largest ethnic group numbering 180 (88%), followed by Chinese 13(6.5%), Indian 3(1.5%) and others 8(4%). The major risk factor identified was intravenous drug use in 107 (52%) followed by sexual activity 20 (10%), haemodialysis 6 (3%) and blood transfusion 4 (2%). 30 (14%) individuals had co-infection with hepatitis B or HIV, a significant number of them female (20%).

Conclusions

The most frequently identified risk factor for hepatitis C is intravenous drug use especially in young and middle age males. In females the leading risk factor is through sexual contact. It is important to identify the high risk population for screening and initiating preventive and treatment strategies.

RECTAL FOREIGN OBJECTS, DOES THE CARE ENDS AFTER REMOVAL? - A CASE REPORT AND LITERATURE REVIEW

Henry Tan Chor Lip, Seniyah Md Sikin, Tan Jih Huei

General Surgery Department, Hospital Sultan Ismail, Johor Bahru, Johor, Malaysia

Introduction

Insertion of rectal foreign body for purposes of sexual pervertism, self gratification, accidentally or voluntarily has been described since the 16th century. The true incidence rate in our population is unknown as many cases goes unreported due to the nature of the condition .

Objective

A case presentation and literature review on management of retained rectal foreign bodies.

Case Presentation

A 48 years old male with no previous medical history was presented with constipation and abdominal pain for 3 days. History revealed that he had inserted a sex device into his anus for sexual satisfaction but was unable to remove it.

Discussion

An abdominal radiograph was performed and revealed a foreign body shaped oval longitudinal in the rectum. Attempts at removing it manually via per rectal and colonoscopy failed. He was taken to operation theatre and successfully removed with muscle relaxant subsequently with suprapubic pressure.

Conclusion

Rectal foreign bodies is easily diagnosed with a plain radiograph. Its management varies on individual presenting symptoms and clinical assessment. A successful removal is not complete without post removal care selective colonoscopy and a referral to the physiatrist for treatment of such abnormal behavior.

ABDOMINAL ACTINOMYCOSIS: A FORGOTTEN DISEASE

B H Ooi¹, M R Hassan¹, Z Zalwani¹, M S Firdaus¹, C H Loo², K K Kiew¹

¹Department of Internal Medicine, Hospital Sultanah Bahiyah, Alor Setar, Kedah, Malaysia

²Department of Internal Medicine, Hospital Sultan Abdul Halim, Sungai Petani, Kedah, Malaysia

Introduction

Actinomycosis is a rare, chronic and slow-growing granulomatous disease caused by Actinomyces species which are part of the native microbiota found in oropharynx, gastrointestinal and urogenital tract. Abdominopelvic actinomycosis contributes to one-fifth of the cases reported with the ileo-caecal region being the most common area involved. Being the great pretender, actinomycosis can mimic other conditions like tuberculosis and malignancy. Clinical, laboratory and radiological manifestations of abdominal actinomycosis remains non-specific. Pre-operative diagnosis is extremely rare and is only established in 10% cases.

Case Description

We report the case of a 21 year old single lady presenting with classic symptoms and clinical signs of acute appendicitis. She underwent emergency operation which revealed an appendicular mass surrounded by unhealthy caecum. Appendectomy with limited right hemicolectomy was performed. Subsequent histopathological analysis of the resected specimen revealed Gram positive filamentous organisms and sulphur granules, confirming actinomycosis. She was treated with 2 weeks of crystalline penicillin G followed by 6 months of oral penicillin.

Conclusion

With its declining prevalence over the years with diagnostic difficulty, it comes as no surprise that there is a lack of cases reported. High index of suspicion is therefore crucial for early diagnosis and treatment. Our case illustrates that abdominal actinomycosis may not be that rare but rather an under-diagnosed forgotten disease.

BLEEDING ILEAL LIPOMA: AN EXTREMELY RARE PRESENTATION OF ANEMIA IN ADULTS

B H Ooi¹, M R Hassan¹, Z Zalwani¹, M S Firdaus¹, C H Loo², K K Kiew¹

¹Department of Internal Medicine, Hospital Sultanah Bahiyah, Alor Setar, Kedah, Malaysia

²Department of Internal Medicine, Hospital Sultan Abdul Halim, Sungai Petani, Kedah, Malaysia

Introduction

Small bowel tumours are extremely rare clinical entities, accounting only 1% to 2% of all gastrointestinal (GI) tract tumours, despite the small bowel comprising 75% of the length and 90% of the GI tract surface area. Most are benign and lipoma makes up 15% of these tumours. Patients are generally asymptomatic and remain so throughout their life. Despite exhaustive diagnostic workouts, these tumours may remain 'hidden' pre-operatively.

Case Description

We report the case of a 27-year-old man with a rare case of obscure GI bleeding. He presented with 1-week history of symptomatic anemia requiring blood transfusion with malaena. He however had no abdominal pain and examination was unremarkable. Oesophagogastroduodenoscopy (OGDS) and colonoscopy revealed no cause of bleeding. Eventually, video capsule endoscopy (VCE) revealed a polypoid mass over distal ileum and a follow-up computed tomography (CT) abdomen revealed wall thickening with intussusception. Exploratory laparotomy confirmed the presence of ileal intussusception with small bowel tumor in within. Segmental resection was done with primary end to end anastomoses. Histopathological examination revealed benign mature adipocytes which confirmed lipoma.

Conclusion

Our case illustrates the importance of newer modalities such as VCE and the rare potential of a benign lipoma in causing serious GI bleeding.

FIGHTER OR GENOMICS? SURVIVING A DECADE OF LIVER CANCER CONSERVATIVELY

B H Ooi¹, M R Hassan¹, Z Zalwani¹, M S Firdaus¹, C H Loo², K K Kiew¹

¹Department of Internal Medicine, Hospital Sultanah Bahiyah, Alor Setar, Kedah, Malaysia

²Department of Internal Medicine, Hospital Sultan Abdul Halim, Sungai Petani, Kedah, Malaysia

Introduction

An estimated 695,900 liver cancer death occurred worldwide in 2008. Based on United States statistics, 5-year survival rate is only 15%. Low survival rate is attributable to the concomitant liver cirrhosis, which in itself is fatal.

Case Description

We present a case of a 65-year old lady who survived a decade despite being diagnosed with liver cancer in a cirrhotic liver. She had chronic hepatitis C infection but achieved sustained viral response following therapy with pegylated interferon and ribavirin in 2005. A year later, she was diagnosed with liver cancer during surveillance. The cancer measured 2.2 x 2.6 x 1.7 cm in segment 2. Surgery was not an option due to her poor liver reserve. She was not keen on further treatment and opted for conservative therapy. Repeated computed tomography scan after 5 years revealed the tumour had doubled in size to 4.2 x 5.8 x 4.2cm with other new lesions. Regular monitoring of alpha-fetoprotein showed a steady rise from the initial hundreds to thousands and finally >10,000ng/mL. She remained asymptomatic until her tenth-year when she started experiencing liver decompensation. Despite a known poor survival outcome, she defied all odds to live a decade with ECOG (European Cooperative Oncology Group) score of 1 despite no cancer treatment.

Conclusion

Liver cancer is highly heterogenous and cancer genomics may hold the key to explaining the aggressiveness and indolence of certain cancer subtypes. By unlocking this, we may one day individualize liver cancer treatment. Some may not require aggressive treatment regimes where the benefits and risks need to be weighed against survival prognosis.

EOSINOPHILIC ESOPHAGITIS AND NON-EROSIVE REFLUX DISEASE IN AN ENDOSCOPED ADULT MALAYSIAN POPULATION WITH REFLUX SYMPTOMS

Noorlina Nordin¹, NorAizal Che Hamzah², Sharifah Emilia¹, Ong Ean Wah¹, Norhaliza Hassan¹, Mung Seong Wong¹, Syed Hassan Syed Abdul Aziz¹, Hoi Poh Tee³, Yeong Yeh Lee¹

¹School of Medical Sciences, Universiti Sains Malaysia, Kota Bharu, Kelantan, Malaysia

²Hospital Pakar KPJ Pasir Gudang, Johor Bahru, Johor, Malaysia

³Hospital Tengku Ampuan Afzan, Kuantan, Pahang, Malaysia

Background

Asian reports on eosinophilic esophagitis (EoE) are scarce. Features of EoE and non-erosive reflux disease (NERD) may overlap. We aimed to investigate for EoE and NERD in an adult Malaysian population.

Methods

Sequential participants with reflux symptoms were consented. Erosive esophagitis and gastric lesions were excluded. Biopsies were taken at 5, 10 and 15 cm above the SC junction. Endoscopic features (white exudates/WE, congested mucosa/CM, circular rings/CR, linear furrows/LF and stricture) were documented. EoE was defined as eosinophils ≥ 15 /hpf and histological eosinophilia < 15 /hpf. 24-h pH studies were performed in consented participants. Acid exposure was DeMeester score > 14.72 .

Results

Of 120 participants, three had EoE (age 47-49 years; females two; Malays two; all three had allergy) and 81 (mean age 47.8 years; males 48%; Malays 80%; 7% with allergy) had NERD. With EoE, one had dysphagia, all three had WE, one CR and one LF but none had strictures. With NERD, 2.5%, 4.9% and 2.5% had histological eosinophilia at 5, 10 and 15 cm respectively. Also in NERD, 63% had WE, 46% CM, 44% CR and 26% LF. The median (IQR) DeMeester score in 28 NERD participants was 4.94 (11.90), with acid exposure near significance with WE (P=0.08) but not CR (P=0.3) and LF (P=0.6).

Conclusion

EoE prevalence is low at 2.5% with mild symptoms, similar to other Asian reports. Both EoE and NERD share similar clinical and endoscopic features. Allergy history and histology can differentiate the two. WE is a marker for acid exposure and LF and CR are probably more specific for EoE.

SIGNIFICANT RISK OF LIFE THREATENING INFECTIONS IN ELDERLY PATIENTS WITH INFLAMMATORY BOWEL DISEASE RECEIVING ANTI-TNF THERAPY

Ahmad Najib Azmi^{1,3}, Way-Seah Lee², Ruey Terng Ng², Sik-Yong Ong², Sanjiv Mahadeva¹,
Khean-Lee Goh¹, Ida Hilmi¹

¹Department of Medicine, University of Malaya, Kuala Lumpur, Malaysia

²Department of Paediatrics, University of Malaya, Kuala Lumpur, Malaysia

³Department of Medicine, University Sains Islam Malaysia, Kuala Lumpur, Malaysia

Introduction

Anti tumour necrosis factor (anti-TNF) is highly effective in inflammatory bowel disease (IBD) but has been associated with a risk of infectious complications, particularly in patients with advanced age.

Aims

To determine the risk of infectious complications in our elderly patients exposed to anti-TNF therapy.

Methods

This is a retrospective study carried out in the University of Malaya Medical Centre, Kuala Lumpur where all patients diagnosed with IBD on anti-TNF were recruited. Dose and duration of anti-TNF, concomitant medications and infectious complications (non IBD related) were recorded.

Results

349 patients with confirmed IBD who were actively under follow up as from January 2010-2015 were identified. Of all patients who received anti-TNF, 71 were <60 years, 3 were ≥60 years. There was no significant difference in the use of concomitant immunomodulators in the two age groups. Infectious complications were seen in 9(12.7%) in the younger group and 3(100%) in the elderly group. In the young age group, only one (1.4%) died from nosocomial pneumonia following an iatrogenic pneumothorax. 2 patients developed pneumonia (successfully treated) and 6 patients developed shingles. In contrast, all three (100%) of the elderly patients had significant infectious complications; one had disseminated Tuberculosis, one died following nosocomial pneumonia and one developed multiple opportunistic infections (pneumocystis pneumonia, cryptococcal meningitis).

Conclusions

Anti-TNF has to be used with extreme caution and ideally avoided in elderly patients with IBD.

CHANGES OF DISTRIBUTION OF HEPATITIS C GENOTYPE IN PAHANG, MALAYSIA IN THE PAST DECADE: IS THERE ANY?

M H Hasmoni¹, K A Jaafar¹, A Che Aun², H P Tee²

¹International Islamic University Malaysia, Kuantan, Pahang, Malaysia

²Hospital Tengku Ampuan Afzan, Kuantan, Pahang, Malaysia

Objectives

To analyse the different distribution of HCV genotypes, demographic pattern, risk factors and treatment availability between two periods of time.

Methods

This is a hospital-based cohort of 133 chronic hepatitis C patients, collected prospectively among subjects attending Hospital Tengku Ampuan Afzan, Kuantan. We assessed the rate and distribution of HCV genotypes during two consecutive periods, from 2005 to 2006 and from 2013 to 2014, according to age, gender, race and risk factors, as well as treatment received.

Results

	First cohort (2005/2006)	Second cohort (2013/2014)
	N (%)	N (%)
Gender: Male	46 (70.8)	59 (86.8)
Female	19 (19.2)	9 (13.2)
Race: Malay	41 (63.1)	51 (75.0)
Chinese	20 (30.8)	15 (22.1)
Indian	4 (6.2)	2 (2.9)
Others	1 (1.5)	0 (0)
Treatment: Yes	35 (53.8)	54 (79.4)
No	30 (46.2)	14 (20.6)
Risk factors: Unknown	27 (41.5)	22 (32.4)
IVDU	19 (29.2)	32 (47.1)
Blood transfusion	8 (12.3)	7 (10.3)
Sexual promiscuity	11 (16.9)	7 (10.3)
Genotype: 1	21 (32.3)	21 (30.9)
3	38 (58.5)	45 (66.2)
4	4 (6.1)	1 (1.5)
6	2 (3.1)	1 (1.5)

Conclusion

There was more male, Malay ethnic, genotype 3 and IVDU patients seen in the latter cohort. Additionally, more patients in the latter cohort received the appropriate treatment ($p < 0.05$).

EFFICACY AND SAFETY OF PROPHYLACTIC SUPPOSITORY DICLOFENAC IN PREVENTION OF POST-ERCP PANCREATITIS (PEP) IN HIGH RISK PATIENTS IN SELAYANG HOSPITAL

H F Khoo¹, T S Lee², X Y Lim¹, Nur Farhana Mohd Noor¹, K M Voon¹, P S Chua¹,
Siti Hajar Abdul Kadir¹, Najihah Mohd Termizi¹, Krishnan a/l Raman³

¹Pharmacy Department Selayang Hospital, Selangor, Malaysia

²Hepato-Gastroenterology Department Selayang Hospital, Selangor, Malaysia

³Hepatobiliary Department Selayang Hospital, Selangor, Malaysia

Objective

This study aim to (1) evaluate the efficacy of prophylactic suppository Diclofenac in prevention of post-ERCP pancreatitis (PEP) for high risk patients, (2) evaluate the severity of PEP in high risk patients (mild, moderate, severe), (3) evaluate the safety of administration of suppository Diclofenac.

Methodology

An observational study was carried out from 2011 until May 2015. From 2013, patients at high risk for developing PEP who are undergoing ERCP were given prophylactic suppository Diclofenac 100mg. The incidences of PEP were observed. The efficacy of prophylactic suppository Diclofenac in prevention of PEP will be evaluated by reduction in incidences of PEP compared to a control group untreated with suppository Diclofenac in 2011 and 2012. Patients were followed up for 30 days to observe for adverse events after the administration of suppository Diclofenac.

Results and Discussions

A total of 100 patients were included. PEP developed in 4 (8.0%) patients given suppository Diclofenac (n=50) and in 12 patients (24.0%) in the control group (n=50) [p=0.029]. This difference is statistically significant with an absolute risk reduction (ARR) of 16%, relative risk reduction (RRR) of 66.7% and a number needed to treat (NNT) of 7. Mild and moderate PEP occurred in 1 (2.1%) and 3 (6.4%) patients given suppository Diclofenac. No patients developed severe PEP. In the control group, 2 (4.2%), 9 (18%), and 1 (2.1%) patients developed mild, moderate and severe PEP respectively. There were no bleeding events; acute renal failure; myocardial infarction, stroke or death at 30days follow-up in patients given suppository Diclofenac.

Conclusion

Prophylactic suppository Diclofenac significantly reduced the risk of PEP in high risk patients in Selayang Hospital.

CASE REPORT: FAMILIAL ADENOMATOUS POLYPOSIS FUNDAL GASTRIC CANCER WITH MULTIPLE LIVER METASTASIS

Tee Teong Jin¹, Nimalarajan Kanagarajan², Joharuddin Bin Md Kasim³

¹Medical Department, Nilai Medical Centre, Nilai, Negeri Sembilan, Malaysia

²Surgical Department, Nilai Medical Centre, Nilai, Negeri Sembilan, Malaysia

³Radiology Department, Nilai Medical Centre, Nilai, Negeri Sembilan, Malaysia

Introduction

Familial Adenomatous Polyposis (FAP) is the most common adenomatous polyposis syndrome. It is characterized by the progressive development of hundreds to thousands of adenomatous polyp in the large intestine. FAP has an incidence at birth of about 1/8,300, it manifests equally in both sexes. The development of Gastric adenocarcinoma in FAP patients is rare .

Case Report

We present a 44 year-old male patient with past history of FAP colon cancer post total proctocolectomy with conventional ileostomy in year 2004 presented with abdomen distension, sclera jaundice for 1 month. This patient with strong family history of FAP, his mother died of FAP colon cancer at age 38 year-old, one uncle and two aunts on maternal side suffered from FAP colon cancer as well. Genetic testing was done in one local hospital. Patient defaulted endoscopy follow up post operation. Thorax, abdomen and pelvis CT was done revealed that an irregular mass 6.6x5.9x5.4cm at fundus extends to the body of stomach lesser curvature and GE junction, multiple lymphadenopathy over abdomen cavity. Liver is enlarged with multiple hypodense liver lesions. OGDS was done with huge gastric fundal mass and multiple polyps over the antrum, body and duodenum. Lab results Hb 10.1g/dl, WBC 20300/ul, CEA 141ng/ml, Bilirubin Total 23.3umol/l, GOT 108U/L, GPT 64U/L, Alk-P 349U/L, GGT 696 U/L. HPE of gastric with gastric fundal polyp (polypoidal tissue specimen) High grade Villous adenoma with area of invasive poorly differentiated carcinoma. Diagnosis: FAP gastric cancer stage IV with multiple liver metastasis. Owing to terminal stage of disease, patient not keen for chemotherapy and defaulted follow up after discharge .

Discussion

The incidence rate of gastric cancer, duodenal cancer and periampullary cancer are high in patient with FAP.

Conclusion

Surveillance of Upper GI endoscopy with forward and side - viewing endoscopes every 1-3 years start at time of colectomy is strongly recommended for FAP patients.

CASE REPORT: PRIMARY DIFFUSE LARGE B CELL LYMPHOMA OF THE CAECUM AND ASCENDING COLON

Tee Teong Jin¹, Nimalarajan Kanagarajan²

¹Medical Department, Nilai Medical Centre, Nilai, Negeri Sembilan, Malaysia

²Surgical Department, Nilai Medical Centre, Nilai, Negeri Sembilan, Malaysia

Introduction

The gastrointestinal (GI) system is a common site for secondary spread of non-Hodgkin.

lymphomas (NHL). Primary involvement of the GI tract is significantly less common, representing only 10-15% of all NHLs and accounting for approximately 4% of all tumors arising in the GI system.

Case Report

This 61 year-old female with past history of Diabetes Mellitus, hypertension and hyperlipidemia presented with anemia, abdominal pain and bowel habit change for 1 month. She was referred from other institution. Physical Examination revealed that her conjunctiva was pale, lower abdomen was tenderness without shifting dullness. Blood test result revealed that Hb 7.8g/dl, Platelet 797000, MCV 71fl, WBC 13500, Iron 1.2ug/dl, CEA 1.1 ng/ml, Albumin 27g/l. Abdomen CT scan was done revealed that cancer of caecum with metastases to intra abdominal nodes. Liver and spleen with some hypodensity lesions suspicious of metastasis. Gastroscopy was done with tiny fundus gastric polyp, Colonoscopy with large caecal tumor and rectal polyp. HPE result: caecal tumor poorly differentiated carcinoma. Operation of Exploratory laparotomy and right hemicolectomy were performed smoothly. Histopathology report diffused large B cell lymphoma involving caecum and ascending colon. Patient discharged after operation and continue chemotherapy in Government Hospital.

Discussion

Primary colorectal lymphoma is a rare malignancy accounting for 3% of all GI Lymphomas and 0.1-0.5% of all colorectal malignancies. The stomach is the most common location of GI lymphomas (50-60%) followed by small bowel (20-30%) and colorectal (10-20%) lymphomas. Diffuse large B-cell lymphoma is the most common histological subtype lymphoma

Conclusion

Primary colorectal lymphomas are rare malignancies. The most common histological subtype of colorectal lymphoma is diffuse large B-cell lymphoma

MONO OR DUAL THERAPY, ARE WE FOLLOWING THE STANDARD? AN AUDIT OF UPPER GASTROINTESTINAL BLEEDING

Henry Tan Chor Lip¹, Nur Fitriyani Afiqah², Tan Jih Huei¹

¹General Surgery Department, Hospital Sultan Ismail, Johor Bahru, Johor, Malaysia

²Newcastle University Medicine Malaysia, Johor Bahru, Johor, Malaysia

Introduction

Acute upper gastrointestinal bleeding (UGIB) is a common surgical emergency with a 10% mortality. It is one of the main cause for hospitalization worldwide.

Methods

This is a retrospective cohort study conducted in Hospital Sultan Ismail from August to October 2014. All emergency endoscopy performed were included. The objective of this study is to audit the adherence of endoscopy therapy and usage of PPI in treatment of acute non-variceal UGIB in accordance to National Institute for Health Excellence (NICE) 2012 UGIB guidelines.

Results

A total of 78 patients were included with male to female ratio 3:2 and mean age of 58.5 years. Only 29% (24) required endoscopy interventions of mono or dual therapy whereas the remaining had diagnostic endoscopy. 78.3% (19) had dual or triple therapy of adrenaline added with another modality for hemostasis, whereas 21% (5) received only monotherapy. 93.6% of the patients was started on a single form of proton pump inhibitor (PPI's) prior to endoscopy whereas 97.4% of patients was started on PPI's after endoscopy.

Discussion

Forrest classification of 2C or 3 in peptic ulcer disease indicates low risk of re-bleeding and thus single modality of endoscopy or PPI treatment might be sufficient to treat the ulcer. Studies also show that low risk stigmata do not benefit from endoscopy therapy and should not be treated endoscopically.

Conclusion

In our centre, majority of patients received dual therapy as per the international guidelines. However, the decision for method of endoscopic hemostasis still depends on ulcer risk and on the experience of the endoscopist.

SPYGLASS® CHOLANGIOSCOPY FOR LARGE CHOLEDOCHOLITHIASIS WITH A REUSED SPYSCOPE: A SINGLE-CENTRE EXPERIENCE (CASE SERIES)

Shiaaw-Hooi Ho¹, Sanjiv Mahadeva¹, Sook-Hui Chaw², Pui-San Loh², Khean-Lee Goh¹

¹Department of Medicine, University of Malaya, Kuala Lumpur, Malaysia

²Department of Anaesthesiology, University of Malaya, Kuala Lumpur, Malaysia

Objective

SpyGlass® cholangioscopy is a recent innovation in single-operator biliopancreatic endoscopic therapy. However, it is limited by its cost, primarily due to the use of disposable accessories in the SpyGlass system. The utility of re-using these accessories, with the potential benefit of reducing the overall cost of the SpyGlass® procedure, has not been reported to date.

Methodology

We report a series of 8 patients who underwent Spyglass® cholangioscopy for difficult-to-remove choledocholithiasis. Electro-hydraulic lithotripsy (EHL) was used to achieve lithotripsy followed by basket and balloon trawling of the bile duct. Propofol sedation was given for these 8 patients. A total of 2 SpyScopes were reused for these 8 procedures.

Results

Eight patients underwent Spyglass® cholangioscopy consecutively between 2013 and 2015. 62.5% were male and 37.5% were female. The mean age was 66.636.9-year-old. The mean size for largest detected stone was 15.931.9mm. The median number of ERCP procedures before subjecting a patient for Spyglass® cholangioscopy was 2 and the median number of ERCP procedures after Spyglass® was 0. Clinical success for Spyglass cholangioscopy with EHL in achieving complete stone clearance in a single attempt was 75% (6/8 cases). The remaining two cases each required additional one conventional ERCP procedure to complete the stone clearance. Median hospital stay after SpyGlass procedure was 1 day. No procedure-related complications such as cholangitis or haemobilia was observed in this case series.

Conclusions

Repeated usage of the SpyScope, up to at least 4 Spyglass® procedures on average, appears to be safe and effective in the management of difficult choledocholithiasis.

HIGH DOSE AMOXICILLIN-DEXLANSOPRAZOLE DUAL THERAPY IS A PROMISING SECOND LINE RESCUE THERAPY FOR *H.PYLORI* INFECTION

Alex Hwong-Ruey Leow¹, Ahmad Najib Azmi², Khean Lee Goh¹

¹Division of Gastroenterology and Hepatology, Department of Medicine, Faculty of Medicine, University of Malaya, Kuala Lumpur, Malaysia

²Faculty of Medicine and Health Sciences, Universiti Sains Islam Malaysia, Kuala Lumpur, Malaysia

Background & Aims

H.pylori eradication failures are getting more and more difficult to treat due to increasing resistance trend towards clarithromycin and levofloxacin. This study is aim to determine the effectiveness of two weeks high dose dual therapy comprising of amoxicillin (Ospamox) 1g q.i.d and dexlansoprazole (Dexilant) 60mg b.i.d.

Methods

Consecutive patients who failed 1st line triple therapy were recruited. *H.pylori* status was determined by a C13 urea breath test performed at least four weeks post treatment.

Results

As an ongoing study, 25 patients have been recruited thus far. Intention-to-treat eradication rate was 80.0% (20/25) (95%CI: 60.87%-91.14%) and per-protocol eradication rate was 83.3% (20/24) (95%CI: 64.15%-93.32%). The treatment was generally well tolerated. Two patients developed giddiness while one patient each complained of diarrhea, anorexia, belching and retrosternal burning sensation. All side effects were considered mild.

Conclusion

High Dose Dual Therapy appears to be a good rescue therapy for *H.pylori* treatment failures.

A REVIEW OF CAPSULE ENDOSCOPY STUDIES IN HOSPITAL AMPANG

Sudarshan Krishnamurthi, Sattian Kollanthavelu, Rosaida Md Said

Hospital Ampang, Selangor, Malaysia

Background

Capsule endoscopy (CE) is a noninvasive technology that can provide diagnostic imaging of the small bowel. Our centre has offered this service since 2012. It is indicated in the investigation of obscure GI bleed (OGIB), Crohn's disease involvement of the small bowel, and the evaluation of small bowel polyps or tumours.

Objective

The primary objective of this study is to assess the diagnostic yield at our centre.

Methodology

This is a retrospective study of 19 patients that underwent CE at our centre between May 2012 to May 2015.

Results

14 patients were investigated for OGIB, 2 patients for suspected Crohn's disease and 3 patients for small bowel polyps or tumours. 10 patients (71.4%) had positive findings for OGIB, whereas all our patients investigated for Crohn's disease had positive findings. 1 of the patient was found to have small bowel polyp. In this study our positive findings for OGIB were; small bowel erosions (n= 7, 50%), blood in bowel (n=2, 14.3 %), angiodysplasia (n=1, 7.1%)

Conclusion

CE is a novel non-invasive method of small bowel imaging. Our predominant indication had been for OGIB, for which we had a good yield of positive findings. It is also a safe procedure, as we encountered no incidence of capsule retention.

SANDORICUM KOETJAPE (SANTOL OR COTTONFRUIT) - INDUCED SIGMOID COLON PERFORATION

Dyg Zahratul Hamrak, Norliana Jaafar, Annisa Zainal Mokhtar, Rashide Yaacob

Department of General Surgery, Hospital Sultan Abdul Halim, Sungai Petani, Kedah, Malaysia

Introduction

Sandoricum koetjape (santol or cottonfruit) is a tropical fruit grown in Southeast Asia. The pulp can be eaten raw, however, santol seeds are inedible and may cause complications such as intestinal obstruction if swallowed. We report a case of a 66-year-old woman who presented with abdominal pain and peritonitis, whereby exploratory laparotomy was performed which revealed sigmoid colon perforation secondary to santol seeds ingestion.

Case Report

A 66-year-old diabetic and hypertensive woman presented with 3 days' history of generalized abdominal pain and peritonitis. CT abdomen revealed perforated viscus complicated with moderate pneumoperitoneum, ascites and paralytic ileus. Bowel perforation was suspected and emergency exploratory laparotomy was performed. Intraoperatively, we found impaction of four santol seeds, largest measuring about 3x2cm with sharp edges which caused perforation at sigmoid colon with severe fecal contamination. Sigmoid colectomy, peritoneal washout and Hartmann's procedure were done. The patient had a good recovery and was discharged well.

Discussion

Foreign body ingestion is a significant problem that causes surprisingly high morbidity and mortality. In the majority of cases, foreign bodies can pass successfully through the proximal oesophageal sphincter and ileocaecal valve, before they are discharged in the faeces. However, in some cases, foreign body ingestion is followed by life-threatening complications, for which surgical intervention is essential, such as perforation and peritonitis, perforation with secondary abscess formation, gastrointestinal bleeding, bowel obstruction or even perforation with injury of adjacent viscera.

Conclusion

Santol seeds ingestion can lead to intestinal obstruction. The pre-operative diagnosis is difficult and despite the wide range of imaging methods, the diagnosis of foreign body complication is usually achieved during operation.

COLLAGENOUS COLITIS: A CASE REPORT

Muhammad Ilham Abdul Hafidz¹, Thevarajaan Jayaraman¹, Effat Omar², Annamalai Chandramouli¹

¹Department of Internal Medicine, Faculty of Medicine, Universiti Teknologi MARA (UiTM), Selangor, Malaysia

²Department of Pathology, Faculty of Medicine, Universiti Teknologi MARA (UiTM), Selangor, Malaysia

Objective

We report a case of collagenous colitis presenting in a patient with intermittent bloody loose stools.

Presentation

A 38 year old Malay man with no known medical illness presented to us with a 6 month history of passing loose stools twice per day, intermittently mixed with fresh blood and associated with abdominal pain. He denied any other symptoms. Colonoscopy showed an inflamed rectum, mild proctitis and an inflamed terminal ileum. Random biopsies were taken and sent for histopathological examination.

Results

Histology of the terminal ileum, caecum, ascending colon, transverse colon, descending colon, sigmoid colon and rectum demonstrated glandular structures which were maintained but slightly dispersed apart due to stromal oedema and mild to moderate chronic inflammatory cell infiltrate comprising lymphoplasmacytic cells. A few areas show presence of an eosinophilic, linear, acellular material demonstrated immediately beneath the glandular basement membrane. These features were in keeping with collagenous colitis.

Conclusion

Collagenous colitis is a rare condition which in most cases will usually settle with conservative management. Long-term follow up is needed in the event of symptom progression, alerting the clinician to perform repeat endoscopy and to consider alternative treatment modalities.

OPTIMISING FIRST LINE *H.PYLORI* ERADICATION THERAPY: PROLONGING TREATMENT OR ADD-ON THERAPY, WHICH IS BETTER?

Alex Hwong-Ruey Leow¹, Ahmad Najib Azmi², Khean Lee Goh¹

¹Division of Gastroenterology and Hepatology, Department of Medicine, Faculty of Medicine, University of Malaya, Kuala Lumpur, Malaysia

²Faculty of Medicine and Health Sciences, Universiti Sains Islam Malaysia, Kuala Lumpur, Malaysia

Background & Aims

The efficacy of treatment of *Helicobacter pylori* infection has decreased steadily because of increasing resistance to clarithromycin. Our aim of this study is to re-examine the efficacy and tolerability of several combination of first-line eradication therapy.

Methods

Consecutive treatment naïve participants with a positive rapid urease test during an outpatient upper endoscopy were included. All participants were randomly assigned to groups given rabeprazole (Pariet) 20 mg b.i.d., amoxicillin (Ospamox) 1 g b.i.d. and clarithromycin (Klacid) 500 mg b.i.d. for 7 days (Group A), 14 days (Group B) and bismuth subcitrate (De-Noltab) 240mg b.i.d, rabeprazole (Pariet) 20mg b.i.d., amoxicillin (Ospmaox) 1g b.i.d. and clarithromycin (klacid) 500mg b.i.d for 7 days (Group C). Successful eradication was defined by negative C13-urea breath test at least 4 weeks after the completion of therapy.

Results

As an interim-analysis, a total of 304 patients were recruited. In the intention-to-treat analysis, *H.pylori* was eradicated in 75.5% of patients in group A, (77/102) (95% CI: 65.32%–82.81%), 87.6% (85/97) (95% CI: 79.61%–92.78%) in group B and 85.7% (90/105) (95% CI: 77.76%–91.15%) in group C. Per-protocol analysis showed that the infection was successfully eradicated in 79.4% of patients in group A (77/97) (95% CI: 70.29–86.24%), 91.4% (85/93) (95% CI: 83.94%–95.58%) in group B and 86.5% (90/104) (95%CI: 78.67%–91.81%) in group C. There were no significant differences between groups in adverse events or patient adherence.

Conclusion

14-day clarithromycin based triple therapy and 7-day bismuth based quadruple therapy are equally as effective and are superior to 7-day clarithromycin based triple therapy.

REVIEW OF UPPER GASTROINTESTINAL ENDOSCOPY PERFORMED IN UiTM IN 2014

Thevaraajan Jayaraman, Rafiz Abdul Rani, Mohd Ilham Abdul Hafidz, Annamalai Chandramouli

Gastroenterology Unit, Department of Internal Medicine, Faculty of Medicine, Universiti Teknologi MARA (UiTM), Selangor, Malaysia

Objective

To determine the common indications and findings for upper gastrointestinal (GI) endoscopies performed in the clinical facilities of UiTM Medical Faculty in 2014.

Methods

All upper GI endoscopies performed in 2014 in the clinical facilities of UiTM Medical Faculty were identified. Endoscopy reports and case notes were reviewed for demographic details, indications and findings.

Results

A total of 169 upper GI endoscopies were performed in 2014. There were 88 female patients and 81 male patients. There were 129 Malay patients, 28 Chinese, 9 Indian, and 3 others.

The commonest indication to perform upper GI endoscopy was dyspepsia, involving 66% of cases (n=112). This is followed by anaemia and/or suspected upper GI blood loss (16%, n=27) and atypical chest pain (7%, n= 12).

The commonest finding was gastritis, involving 70% of cases (n=119). Other findings included oesophagitis (15%, n=25) and duodenitis (9%, n=15). 21 patients were found to have peptic ulcer disease; 16 had gastric ulcers and 5 had duodenal ulcers. Polyps were found in 22% of cases; 20 patients with gastric polyps (12%), 15 with duodenal polyps (9%) and 2 with oesophageal polyps (1%).

Out of 162 patients tested, 9 were CLO test positive and subsequently treated with *H. pylori* eradication therapy. 7% had Barrett's oesophagus (n=11).

For patients with dyspepsia: 69% had gastritis (n=77), 23% had hiatus hernia (n=26), 13% had oesophagitis (n=14), 9% had duodenitis (n=10), 7% had gastric ulcer (n=8), and 5% had Barrett's oesophagus (n=6).

Conclusion

The commonest indication for upper GI endoscopy in UiTM in 2014 is dyspepsia and the commonest finding is gastritis. Other interesting findings of note are that 6% of cases tested positive for *H. pylori* and 7% had Barrett's oesophagus.

ERCP CANNULATION SUCCESS RATE IN A TERTIARY HOSPITAL IN EAST COAST PENINSULAR MALAYSIA: BENCHMARKING WITH STANDARDS

S K Kutty¹, M H Hasmoni¹, K A Jaafar¹, A Che Aun², H P Tee²

¹International Islamic University Malaysia, Kuantan, Pahang, Malaysia

²Hospital Tengku Ampuan Afzan, Kuantan, Pahang, Malaysia

Objectives

Virgin papillae present the most challenging target for endoscopists. This study is to investigate the success rates of cannulating a 'virgin' papilla during endoscopic retrograde cholangiopancreatography (ERCP) at a tertiary referral centre; determine complication rate, reasons for failure and benchmarking with international standards.

Methods

Retrospective study, review of all ERCPs recorded from January 2011 to December 2012 (N=316). 'Virgin' papilla is defined as those with no evidence of prior surgical intervention, stents in situ or sphincterotomy (N=250). All the endoscopists have an ERCP experienced of more than three years.

Results

The mean age was 50.0 ± 15.1 with majority being Malays (78.1%) followed by Chinese (12.4%), Orang Asli (5.6%) and Indian (2.0%). Overall success of cannulation of a virgin papilla at ERCP was 86.4%, 220 out of a total of 250 virgin papillae cases. The success rate for surgeons and physicians were 86.4% and 85.7% respectively. There was no significant difference between the two. Abnormal papilla was the commonest cause of a failed bile duct cannulation. Other causes include duodenal diverticular, tumour impingement and patient agitation/instability. The complication rate was low: acute pancreatitis occurred in 0.5%, haemorrhage in 0.2% and no perforation was documented.

Conclusion

ERCP in our medical centre was associated with a high degree of technical success and a low risk of complications, comparable to the Joint Advisory Group's 80% success rate for completion of therapeutic intent (BSG Quality and Safety Indicators for Endoscopy).

HAEMATEMESIS: A RARE MANIFESTATION OF DISSECTING THORACIC AORTIC ANEURYSM

Dyg Zahratul Hamrak, Norliana Jaafar, Annisa Zainal Mokhtar, Rashide Yaacob

Department of General Surgery, Hospital Sultan Abdul Halim, Sungai Petani, Kedah, Malaysia

Introduction

Aortic aneurysms are relatively common and are potentially life-threatening. Aneurysms are defined as a focal dilatation in an artery, with at least a 50% increase over the vessel's normal diameter. Pain and pulsation are common presenting features of aortic aneurysms. Haematemesis represent rare clinical manifestation. We report the case of a 63-year-old woman with haematemesis who had an acute dissection of a previously undiagnosed thoracic aortic aneurysm.

Case Report

A 63-year-old woman, who is a smoker with a history of well-controlled hypertension and diabetes, presented with cough, chest pain, haematemesis and loss of weight for 1 week duration. Chest radiograph showed a left midzone homogenous opacity with loss of intimal continuity and inability to visualize aortic knuckle. Based on a suspicion of lung carcinoma, CT Angiography of Thorax was done. CT scan showed ascending aortic aneurysm with focal intimal ulceration at aortic arch measuring 3.1cm x 2.5cm x 3.5cm causing intramural leak complicated with extensive chronic leak into the mediastinum and left pleural space. She had multiple episodes of haematemesis in the ward. We performed an oesophagogastroduodenoscopy (OGDS) which showed a large obstructive red lesion in the esophagus, suggesting a large intramural hematoma of the esophagus, with blood clots. The woman was stabilised and an urgent referral was done to a tertiary centre. Unfortunately, shortly afterward, the patient suddenly had a cardiac arrest and haematemesis which became out of control, and she passed away.

Discussion

Dissecting aortic aneurysm may present with haematemesis due to aorto-oesophageal leak or fistula. Aortic dissection is an uncommon but a potentially fatal condition.

Conclusion

A high level of suspicion is required for successful diagnosis and management. Rapid intervention is required because delay leads to higher mortality. Despite advances in diagnostic and therapeutic techniques, mortality and morbidity of dissecting aortic aneurysm is still high.

LIVER FIBROSIS EPIDEMIOLOGY REVISITED USING SOFTWARE COMBINED BIOMARKER: PROOF OF CONCEPT USING 1,081,658 CENTRALIZED FIBROTEST (FT) PRESCRIPTIONS

Thierry Poynard^{*1, 2, 3} on behalf of FibroFRANCE, Olivier Deckmyn⁴, Joe Sebastian⁵, Mona Munteanu⁴, Yen Ngo⁴, Fabienne Drane⁴, Janet Queen⁵, Jean Marie Castille⁴

¹Groupe Hospitalier Pitie Salpetriere APHP

²UPMC

³INSERM UMR S938

⁴BioPredictive, Paris, France

⁵Labcorp, Burlington, United States of America

Objectives

The epidemiology of liver fibrosis (LF) was classically described by liver biopsy (LB), therefore limited by bias of LB indication and sample size. Several LF biomarkers have been validated including FT. We aimed to revisit the epidemiology of LF using the centralized software- combined database (DB) of FT, for assessing the impact of age and sex on LF severity (LFS) as well as the impact of health policy for screening LFS.

Methodology

From 2002 to 2014, 1,081,658 interpretable FT, were performed consecutively on fresh serum, mostly for chronic hepatitis C (CHC). In 5 countries, France (Fr), USA, Romania (Ro), Egypt (Eg) and Morocco (Ma), we compare (R software): LFS (METAVIR scoring system F0 to F4 and cirrhosis severity F4.1 compensated, F4.2 bleeding risk and F4.3 complicated), the density of LFS according to birth-year (BY) and sex, and the progression of FT dissemination. We used as controls a DB of CHC with LB (Lancet 1997 n=2235, Gastro 2002 n=4177).

Results

In France FT was commonly prescribed, with stable rates since reimbursement (2006); a high number of F4 was detected in women born before 1945 (n=20,672). In USA, FT (FibroSure) rate dramatically increased in 2013-2014 when the baby-boomer campaign (BY 1945-1965) started, vs 2011-2012 (+132%) before. In multivariate regression analysis, adjusted for age (OR=1.06) and sex (OR=3.22) and USA as reference (OR=1). Eg had the higher risk (OR=2.3;2.2-2.3) possibly due to associated schistosomiasis. Ma (OR=1.3;1.2-1.3), Ro (1.1;1.1-1.2; masked in univariate (younger age) and lower risk for Fr (0.90; 0.88-0.91); all P<105.

Conclusion

Despite possible bias associated with patented biomarker prescription, this proof-of-concept study permitted already to prepare better strategies to reduce the burden of cirrhosis, based on 200 times more patients than biopsy. The first interpretation for France is to prevent without delay a massive burden of death in women born before 1945.

*Disclosure of Interest: J.M. Castille, O.Deckmyn, Y. Ngo, M. Munteanu: Employee BioPredictive, S. V. Ratziu: None Declared, T. Poynard: Stockholder: BioPredictive, J. Sebastian, Janet Queen: Employee LabCorp.

DIRECT COMPARISONS OF FIBROTEST, APRI, FIB-4, AND TRANSIENT ELASTOGRAPHY (TE) FOR THE DIAGNOSIS OF CIRRHOSIS AND FIBROSIS, IN PATIENTS WITH CHRONIC HEPATITIS C (CHC) AND B (CHB) USING INTENTION TO DIAGNOSE AND BAYESIAN METHODS. A SYSTEMATIC REVIEW

Marion Houot¹, Yen Ngo¹, Mona Munteanu¹, Sebastien Marque², Thierry Poynard^{*3}

¹BioPredictive

²Capionis

³APHP, Paris, France

Objectives

The diagnostic performances of noninvasive tests for the diagnosis of cirrhosis (F4) or clinically significant fibrosis (METAVIR stages F2F3F4) in chronic liver disease (CLD) have been assessed using indirect comparisons and “per-protocol” (PP) analysis, that is, without taking into account the applicability (failure or non reliability) of tests, [“intention-to-diagnose” (ITD)]. The aim was to compare the performance of the four most validated tests (FibroTest, TE, APRI and FIB-4) in patients with chronic liver diseases using only direct comparison, ITD and Bayesian methods.

Methods

Direct comparisons using biopsy as reference were searched (MEDLINE) from 2001 to 2014; four methods were used for AUROCs' difference (AUC-D) in ITD: the descriptive AUC-D (Chou 2013), pooled indirect AUC-D, pooled direct AUC-D and pooled direct Bayesian AUC-D (BayesAUC-D).

Results

Among 1279 biomarker studies identified, 71 studies with 77 groups of patients were included (37 with CHC only, 28 CHB only, and 12 “MixedCB” defined as CHC-CHB >49% of CLD) allowing 185 direct comparisons between the 4 tests' AUROCs; 99 for F2F3F4 (12,725 patients) and 86 for F4 (10,929 patients). The significant (credibility interval) BayesAUC-D were 0.06 in favor of FibroTest vs TE and 0.05 vs APRI; for cirrhosis BayesAUC-D were 0.07 in favor of TE vs APRI and 0.04 for FIB4 vs APRI. Non-applicability rate (median/range) was 0% (0-8%) for FibroTest lower ($P < 0.0001$) than for TE 8% (0-41.8); APRI and FIB4 have no rules for applicability.

Conclusions

This overview, the first focusing on direct comparisons in ITD and using Bayesian meta-analysis, permitted to compare fibrosis biomarkers without the limitations of meta-analyses not taking into account the tests' applicability, and of indirect comparisons. FibroTest had better performance than TE for the diagnosis of F2F3F4, in CHC and CHB, which was not observed by indirect and per-protocol previous meta-analyses.

CASE REPORT : A CASE OF DISSEMINATED TUBERCULOSIS WITH SUBACUTE INTESTINAL OBSTRUCTION SECONDARY TO ILEAL STRICTURE

James Emmanuel¹, Nagaraj Sriram¹, Mandeep Singh¹, Raman Muthukaruppan¹,
Jayaram Menon¹, Kunji Kannan Sivaraman Kannan²

¹Medical Department, Hospital Queen Elizabeth, Kota Kinabalu, Sabah, Malaysia

²Department of Respiratory, Hospital Queen Elizabeth, Kota Kinabalu, Sabah, Malaysia

Introduction

Intestinal tuberculosis primarily involves the distal ileum and cecum, followed by the jejunum-ileum, colon and rectum. Pathogen dissemination is attributed to four mechanisms (i) hematogenous dissemination (ii) swallowing of infected sputum, (iii) ingestion of contaminated food, (iv) contiguous spread from adjacent organs.

Case report

A 30 year old gentleman was diagnosed with smear positive Pulmonary tuberculosis in March 2015 following a presentation of chronic cough with low grade fever for a year. He was commenced on antituberculous treatment but presented again 2 months later with persistent vomiting, diarrhea and progressive abdominal distention for a period of 3 weeks. On admission the patient was ill, and the abdomen was slightly distended. There was no leucocytosis.

A barium follow through series done revealed dilated jejunal loops (maximal diameter of 6.7cm) with delayed passage of contrast from the jejunum and ileum into distal bowel (>6 hours). Laparotomy was carried out a few days later and the surgeons reported of an ileal stricture 100 cm from the ileocecal junction which was partially obstructed. Histopathological examination (HPE) revealed ileal tuberculosis causing ulcerative stricture, and mesenteric tuberculous lymphadenitis.

Also of note was that during this admission patient had developed multiple erythematous plaques with central clearance over both limbs and trunk. HPE concurred with a diagnosis of cutaneous tuberculosis.

Discussion

Abdominal tuberculosis presenting as obstruction is easy to diagnose by obtaining biopsies during surgery, but when it is not presenting with obstruction the signs and symptoms are non-specific and it closely mimics diseases like Crohn's disease, malignancy and peri appendicular abscess. This may lead to delay in diagnosis resulting in increased morbidity and mortality.

Conclusion

Complications of intestinal tuberculosis include perforation, fistula formation, and intestinal bleeding. Obstruction is the most common complication, and it occurs in 12-60% of cases.

AWARENESS AND PERCEPTIONS OF COLORECTAL CANCER AND SCREENING AMONG THE POPULATION IN SABAH

*James Emmanuel¹, Ruben Raj¹, Raman Muthukaruppan¹, Jayaram Menon¹, Chin Suliong²,
Naing Oo Tha², Khin Ye Myint²*

¹Department of Medicine, Hospital Queen Elizabeth, Kota Kinabalu, Sabah, Malaysia

²School of Medicine, Universiti Malaysia Sabah, Kota Kinabalu, Sabah, Malaysia

Introduction

Colorectal cancer (CRC) is the second most commonly diagnosed cancer in women and third most common in men worldwide. Over 1.2 million new cases and 608,700 deaths were estimated to have occurred in 2008. Although regular screening can decrease morbidity and mortality from colorectal cancer, the screening rate in Malaysia is suboptimal.

Objectives

1. To determine the awareness of colorectal cancer and screening in the general population in Sabah.
2. To determine if the public is willing to partake in a screening program if introduced.

Methodology

A random sample of 245 adults received a self-administered questionnaire on socio-demographic characteristics, knowledge on colorectal cancer risks and screening tools, attitudes regarding perceived risk of developing CRC, utility of screening test and health related behaviour.

Results

Only 27.3 % identified low physical activity (modifiable risk factor) as a risk factor for colorectal cancer. There was a significant difference in the level of knowledge of identifying familial history of CRC as a risk factor for CRC between both genders where in the female population were more aware of this. About half of the respondents identified colonoscopy as a screening tool. Personal opinion that screening is useful in CRC prevention was high with a mean of 7.4 (Likert scale). 82.8% of the respondents agreed that CRC may be treated when diagnosed at an early stage and 86.8 % would participate in a CRC screening programme if offered.

Discussion

This study demonstrated a deficit in knowledge of colorectal cancer risk factors and screening modalities among respondents. The contributing factor could be due to lack of health education and poor screening promotional activities as only 29 % stated to have been offered any information on CRC in the past.

Conclusion

This study highlights the need to promote CRC screening activities among the population in Sabah.

IS CONTROLLED ATTENUATION PARAMETER WITH THE XL PROBE MORE ACCURATE THAN THE M PROBE FOR ESTIMATION OF HEPATIC STEATOSIS IN PATIENTS WITH NON-ALCOHOLIC FATTY LIVER DISEASE?

Wah-Kheong Chan¹, Nik Raihan Nik Mustapha², Sanjiv Mahadeva¹

¹Department of Medicine, Faculty of Medicine, University of Malaya, Kuala Lumpur, Malaysia

²Department of Pathology, Hospital Sultanah Bahiyah, Alor Setar, Kedah, Malaysia

Background

Controlled attenuation parameter (CAP) was introduced for the Fibroscan XL probe recently and this may improve the diagnostic performance of CAP to estimate hepatic steatosis in NAFLD patients.

Methodology

Adult NAFLD patients who had a liver biopsy within 6 months were included and were examined with the Fibroscan M and XL probes. Histopathological findings were reported according to the Non-Alcoholic Steatohepatitis Clinical Research Network Scoring System. Subjects without fatty liver on ultrasonography were recruited as controls.

Results

A total of 53 NAFLD patients and 22 controls were included in the analysis. Mean age was 41.3 ± 16.2 years old and consisted of 48.0% male. Mean body mass index was 27.4 ± 6.2 kg per m². The distribution of steatosis grades were as follows: S0 30.7%, S1 16.0%, S2 34.7%, and S3 18.7%. The distribution of fibrosis stages were as follows: F0 58.7%, F1 25.3%, F2 5.3%, F3 6.7%, and F4 4.0%. The AUROC for estimation of steatosis grade ≥ S1, S2 and S3 was 0.94, 0.79 and 0.71, respectively, when using the M probe, and 0.96, 0.81 and 0.70, respectively, when using the XL probe. The AUROC for estimation of fibrosis stage ≥ F1, F2, F3 and F4 was 0.88, 0.96, 0.97 and 0.97, respectively, when using the M probe, and 0.88, 0.92, 0.94 and 0.98, respectively, when using the XL probe. Overall, the XL probe gave higher CAP and lower LSM values when compared with the M probe.

Conclusion

The XL probe did not further improve the diagnostic accuracy of CAP and LSM for the estimation of hepatic steatosis and fibrosis in NAFLD patients, and gave higher CAP value and lower LSM value compared with the M probe.

CROHN'S DISEASE PRESENTED WITH INTESTINAL OBSTRUCTION

Dyg Zahratul Hamrak, Annisa Zainal Mokhtar, Su Kim Peng, Rashide Yaacob

Department of General Surgery, Hospital Sultan Abdul Halim, Sungai Petani, Kedah, Malaysia

Introduction

Crohn's disease (CD) is a disorder of unknown aetiology characterised by transmural inflammation of the gastrointestinal (GI) tract. CD may involve any or all parts of the entire GI tract from mouth to perianal area and is characterised by skip lesions. The signs and symptoms of CD overlap with many other abdominal disorders like tuberculosis, ulcerative colitis, and irritable bowel syndrome. Active cases of CD could be accompanied by extraintestinal complications of immune origin, such as iritis, uveitis and sacroileitis. We describe a patient with Crohn's disease who was diagnosed with the disease by chance because of intestinal obstruction.

Case Report

A 47-year-old gentleman who has previous history of appendicectomy done, presented with five days history of vomiting, associated with epigastric pain, abdominal distension and unable to tolerate orally. Physical examination revealed distended but soft abdomen. Oesophagogastroduodenoscopy revealed benign ulcer at lesser curvature. During observation in ward, patient developed generalized abdominal pain with peritonitis. Ultrasound abdomen revealed peritonitis with moderate free fluid in the abdomen. Exploratory laparotomy was performed. Intra-operatively, noted macerated and unhealthy oedematous hepatic flexure mass. Right hemicolectomy and double barrel stoma were done. Histopathology examination of the resected right hemicolon revealed CD. Post-operatively, patient was started on sulfasalazine and was put on regular outpatient follow up.

Discussion

Diagnosis of CD can be made on the basis of a combination of clinical, laboratory, histologic, and radiologic findings. However diagnosis is not uncommonly made post-operatively when patient presented with intestinal obstruction which implied patient has developed complications such as strictures, fistulation, bleeding and perforation.

Conclusion

The symptoms of CD is at times unspecific and may mimic other intestinal pathologies and CD should be considered when patient presented with acute abdomen.

MESENCHYMAL STEM CELL THERAPY FOR ADVANCED LIVER CIRRHOSIS: A CASE REPORT

Ruveena Rajaram¹, Baskar Subramni², B J Jeet Abdullah¹, Sanjiv Mahadeva¹

¹Pusat Perubatan Universiti Malaya, Kuala Lumpur, Malaysia

²Nichi-Asia Life Science Sdn Bhd, Petaling Jaya, Selangor, Malaysia

Objective

Liver transplantation is the only curative therapy for advanced liver cirrhosis. However, due to the scarcity and limitations of liver transplantation, other alternatives need to be explored. Mesenchymal stem cell (MSC) therapy has been purported to have some benefits in end-stage liver disease. We report the use of MSC therapy in a single patient with advanced cirrhosis in our centre.

Case Report

A 50 year old male had initially presented to this institution with decompensated alcoholic liver cirrhosis in 2010. After abstaining from alcohol, he continued to have complications in the form of persistent ascites, lower limb oedema and intermittent encephalopathy. In 2014, at the request of the patient, we proceeded with autologous MSC transplantation on 2 separate occasions, 40 days apart.

The bone marrow derived MSCs were cultured, evaluated and washed and final cell pellet was administered into the liver via hepatic artery infusion. Prior to injection, sterility tests, Immunophenotyping and karyotyping were carried out to confirm asepsis of the product.

Child-Turcotte-Pugh (CTP) score and biochemical parameters, namely Albumin, Total Bilirubin, INR and Creatinine, were measured prior to 1st & 2nd infusion and at weeks 2, 20 & 45 post 2nd infusion and tabulated as below.

Total bilirubin & CTP score showed good improvement at week 45, with INR and Albumin showing only modest improvement at week 45. However, creatinine level seems to have deteriorated. All parameters, except for Creatinine level showed decline at week 20. Ascites improved throughout this observation period but lower limbs edema remained same.

Conclusion

Autologous MSC transplantation appears to have some benefit for advanced liver cirrhosis, but it is not long-lasting.

TITLE: MODIFIED WHIPPLE PANCREATICO DUODENECTOMY: HOW SAFE IS THIS PROCEDURE IN MALAYSIA?

Bong Jan Jin

Sunway Medical Centre, Petaling Jaya, Selangor, Malaysia

Objective

Whipple procedure is one of the most complex procedures within the abdomen. Reconstruction after resection involves three anastomoses – pancreatic, bile duct, and stomach. The pancreatic anastomosis remains the Achilles' heel of this procedure due to complications frequently arise from the breakdown of this anastomosis. Herein, a case-series of Whipple resection with modified pancreatic anastomosis was reported.

Methodology

A retrospective study was carried out between 01.01.2012 and 31.06.2015. Thirty-six cases of Whipple resections were carried out with the modified pancreatico-gastrostomy reconstruction. This was a single-surgeon experience in a tertiary referral hospital. After pancreaticoduodenectomy, the pancreatico-gastrostomy was performed in two layers (internal and external) using 4/0 PDS sutures, with a short internal stenting of the pancreatic duct. Soft drains were left next to the hepatic and pancreatic anastomoses respectively.

Results

There were 25 females and 11 males with the median age of 59 years old (range 26-77). Classic Whipple resections were carried out in 32 cases, whilst in another 4 cases, Whipple was combined with other procedures (left lateral hepatectomy for hamartoma; debulking wedge segmentectomy for neuroendocrine tumours; portal vein resection and reconstruction, and left oophorectomy for benign cystic teratoma). The median size of the tumours was 30mm (range 8-70mm). Pathological diagnoses included 13 pancreatic adenocarcinoma, 6 ampullary adenocarcinoma, 4 cholangio-carcinoma, 4 chronic pancreatitis, 3 neuroendocrine tumours, 2 GIST, and 3 others. Median operation time was 360 minutes (range 240-550). Negative surgical margins (RO) were observed in 100% of the specimen. Median length of hospital stay was 11.5 days (range 8-35). Serious complications (Clavien-Dindo class III and above) occurred in six cases (16%) and mortality in one case (2.7%). No pancreatic fistula was observed.

Conclusion

Whipple resection with modified pancreaticogastrostomy is a safe technique with low morbidity and mortality (2.7%) when compared to data from the literature.

LAPAROSCOPIC LIVER RESECTION IN MALAYSIA

Bong Jan Jin

Hospital Universiti Kebangsaan Malaysia, Kuala Lumpur, Malaysia
Sunway Medical Centre, Petaling Jaya, Selangor, Malaysia

Objective

Laparoscopic hepatectomy has been accepted as a safe and effective approach in the hands of trained surgeons with experience in laparoscopic and hepatobiliary surgery, but its use remains confined to major hepatobiliary centers. The aim of the current study was to report the experience of laparoscopic hepatectomy in a tertiary hospital in Malaysia.

Methodology

For the initial experience, minor wedge resections were confined to favorable locations; major hepatectomy was only performed in selected cases in the later part of the series. A single surgeon who was trained in advanced laparoscopic and hepato-biliary surgery performed all operations. All cases were performed with totally laparoscopic approach, except for two cases that required hand-port assistances, and in another two cases, single-incision-laparoscopic-surgery (SILS) approach.

Results

Between October 2009 and May 2015, 25 patients underwent laparoscopic liver surgery. The median age of the patients was 59 (range 31-77). There were 13 females and 12 males. The median diameter of the tumour was 45mm (range 10-120mm). Types of operation included 15 left lateral sectionectomies, 11 wedge resections (two of which were in combination with left lateral sectionectomies), and one left hepatectomy. The median operation time was 165 minutes (range 65-270). Five cases required conversion from laparoscopic to open surgery: 3 cases were converted early because of dense adhesion, difficult tumour location at segment seven, and inadvertent small-bowel injury, respectively. Two cases were converted late due to haemorrhage and tumour invasion of diaphragm, respectively. Twenty-three out of 25 (92%) patients suffered no post-operative complication except for one case of wound infection and one case of urinary retention requiring catheterization. Median length of stay was 4.5 days (range 2-17).

Conclusion

Laparoscopic liver resection can be carried out successfully in carefully selected cases in Malaysia with low complication rate.

DIAGNOSTIC UTILITY OF ENDOSCOPIC ULTRASOUND-FINE NEEDLE ASPIRATION FOR PANCREATIC CARCINOMA – A RETROSPECTIVE STUDY IN UNIVERSITY MALAYA MEDICAL CENTRE

J E Tai^{1,3}, W K Chan^{1,3}, Rajesh Kumar^{1,2}, B K Yoong¹, K L Goh², I Hilmi²

¹University of Malaya, Kuala Lumpur, Malaysia

²University Putra Malaysia, Selangor, Malaysia

³University of Sydney, New South Wales, Australia

Background

The use of endoscopic ultrasound-fine needle aspiration (EUS-FNA) has enabled tissue acquisition of lesions previously difficult to access radiologically.

Objectives

To determine the utility of EUS-FNA in diagnosing pancreatic cancer and analyse factors contributing to its accuracy.

Methodology

Data from consecutive patients who underwent EUS-FNA for suspected pancreatic cancer from January 2008 to February 2015 in the University Malaya Medical Centre (UMMC) were evaluated retrospectively. Procedural factors contributing to accuracy were also studied.

Results

83 patients underwent EUS-FNA for suspected pancreatic cancer but only 64 had sufficient data for analysis. 34 patients had a final diagnosis of pancreatic adenocarcinoma. The overall accuracy of EUS-FNA in UMMC was 71.8%, with a sensitivity of 55.8% (19/34) and specificity 100% (12/12). However, the overall accuracy increased from 55.9% to 78.8% when comparing between the years 2008-2012 and 2012-2015. When cytological samples reported as "atypical" were considered positive, sensitivity was improved to 76.5% (26/34) at the cost of a lower specificity of 75% (9/12). The use of a 25-gauge needle was found to improve accuracy over a 22-gauge needle [93.3% vs. 61.9% ($p=0.03$)]. Lesions which underwent ≥ 3 passes during the procedure were found to have better yield than ≤ 2 passes (87.5% vs 66.7%) but this difference was not statistically significant ($p=0.577$) given the small sample size. The availability of rapid on site cytopathological examination (ROSE) was also associated with improved accuracy (73.5% vs 66.7%) but this finding was not statistically significant ($p=0.584$).

Conclusion

Our results show that EUS-FNA is a reasonably accurate diagnostic modality for assessing pancreatic lesions. Sensitivity is improved by the use of 25-gauge needles, undertaking ≥ 3 needle passes and on site evaluation.

A RARE CASE OF CONGENITAL MESSENERIC DEFECT – A CASE REPORT

Raveen K, Theebanraja R, Rudyanto, Balasingh D

Hospital Tuanku Ampuan Najijah, Kuala Pilah, Negeri Sembilan, Malaysia

Introduction

Internal hernias secondary to Congenital Mesenteric Defect (CDM) in infants are rare. CDMs constitute only 8% of internal hernias. The clinical presentation is usually non specific, mostly presenting with abdominal pain, distension, bilious vomiting and constipation. Due to nature of the pathology diagnosis of CMD is often overlooked. Child presenting with CMD may be asymptomatic and often present in shock.

Case report

A 3 month old baby boy presented with acute onset of abdominal distension, bilious vomiting, no bowel opening and inconsolable cry for 18 hours. On presentation child was pale, tachypnoeic, grunting and tachycardic. Per-abdomen was distended with bluish discoloration over the umbilicus, bowel sounds were diminished. He was intubated for severe metabolic acidosis and impending cardio respiratory collapse. The plain abdominal X-ray showed a round opacity occupying the right lumbar, central region and no dilated bowel. A diagnosis of bleeding nephroblastoma was made and emergency laparotomy was done. Intraoperatively there were loops of gangrenous small bowel that have herniated through a mesenteric defect measuring 1.0cm x 1.5cm. Approximately 30cm of small bowel, 70cm from the ileocaecal junction was resected and an end to end anastomosis done using Vicryl 4/0. Child was started on Total Parenteral Nutrition and nursed in intensive care unit where he improved progressively.

Discussion

The diagnosis of CMD is challenging due to lack of radiological or laboratory findings to confirm the diagnosis. CMDs can present as segmental defects or basilar defects and mostly are in the ileocaecal mesentery. Adjacent bowel may get trapped in the defect resulting in ischaemia and gangrene. Because of the vague clinical manifestation and low incidence, preoperative diagnosis is often difficult or missed and can lead to mortality. In an infant presenting as such it is important to recognize the possibility of bowel ischemia and urgent intervention must be done.

THE MYSTERY OF THE WHITE LESIONS – A CASE REPORT

M F Limun¹, R Abdul Rani², C S Ngiu¹, R A Raja Ali¹

¹National University of Malaysia (UKM), Kuala Lumpur, Malaysia

²Universiti Teknologi MARA (UITM), Selangor, Malaysia

Objective

Colonic pseudolipomatosis is a rare condition usually incidentally found on colorectal cancer screening. We present a classical presentation of colonic pseudolipomatosis, which are often under-reported.

Presentation

A 51 year old Chinese lady presented with non-specific abdominal pain. No history of altered bowel habits, constitutional symptoms and no significant family history. Clinical examinations were unremarkable. Ultrasound abdomen was normal. Routine bloods were normal with the exception of total cholesterol 5.51 mmol/L, L-DL 3.69 mmol/L, triglyceride 1.49mmol/L.

Results

She subsequently underwent colonoscopy, revealing erythematous thickening distally at the transverse colon. The thickening was covered with elevated whitish plaques, which remains despite copious flushing.

Histology shows lymphocytic infiltration and plasmacytosis within the lamina propria. Numerous clear vacuoles were present. There were no evidence of dysplasia or malignancy

Discussion

This case illustrates a rare finding of colonic pseudolipomatosis based on endoscopic and histology appearance. It has a prevalence rate of less than 0.3% and may present from asymptomatic to a myriad of abdominal pain, altered bowel habits or even per rectal bleeding.

Histology is defined by empty vacuoles with negative specific histochemistry; therefore confirming absence of other material within. Staining by Oil Red O stain mucicarmine stain, alcian blue stain and PAS reaction will commonly indicate absence of mucinous or lipoidal material. Immuno-staining of protein S-100, CD31 and CD34 uptake further indicates absence of adipocytes and lymphatics.

There is no specific treatment for colonic pseudolipomatosis. It usually regresses after three to 20 months. Although believed to be benign, the dearth of information makes it uncertain to comment on long term consequences.

Conclusion

Although rare, colonic pseudolipomatosis is probably under-reported due to its transient nature. Pathogenesis, clinical correlation and complications remained poorly elucidated. Long term observational studies are sorely required for the understanding of this mysterious condition.

AMOEBCIC COLITIS; ANOTHER GREAT MIMICKER? – A CASE REPORT

R Abdul Rani¹, M F Limun², C S Ngiu², R A Raja Ali²

¹Universiti Teknologi MARA (UITM), Selangor, Malaysia

²National University of Malaysia (UKM), Kuala Lumpur, Malaysia

Objective

In Malaysia, the reported prevalence rate for amoebic colitis ranges from 1% - 40%, with higher prevalence noted in immunocompromised patients. We report a case of Amoebic colitis diagnosed during investigations for symptomatic anaemia.

Presentation

A 71-year-old gentleman with long standing Type 2 Diabetes mellitus presented with lethargy. He also had significant weight loss for three months but no abdominal pain, altered bowel habits or rectal bleeding. No travel history documented. Although cachectic, clinical examinations were otherwise unremarkable. Routine blood investigations revealed iron deficiency anaemia with normal renal and liver function. Stool microscopy and culture were negative.

Results

Oesophagus-gastro-duodenoscopy performed was normal. Subsequent colonoscopy showed three areas of erythematous and thickened mucosal wall with surface ulceration. One lesion was located at caecum and the remaining at the ascending colon.

Histology shows infiltrations of inflammatory cells within lamina propria. Numerous *Entamoeba histolytica* were identified. There was no dysplasia or malignancy. Computed tomography of the abdomen concurs with multiple lesions suggestive of infective nature or malignancy.

Discussion

This case illustrates how amoebic colitis easily mimics the presentations of colorectal cancer or even inflammatory bowel diseases as evident by the colonoscopic findings. It usually appears as flask shaped ulcers with presence of *E. histolytica* and inflammatory cells infiltration.

The conventional method of stools examination carries a poor sensitivity.

Common anti-amoebic drug is Metronidazole 500mg TDS for 5-10 days followed by Paromomycin 25-35mg/day for another 5-10 days to eradicate intraluminal infestation.

Conclusion

Amoebic colitis should be considered as a differential in cases of colorectal cancer and inflammatory bowel diseases especially in a tropical country like ours.

IDENTIFICATION OF MOLECULAR CHARACTERIZATION OF SOMATIC MUTATIONS USING TARGETING SEQUENCING IN DUKES' B AND C COLORECTAL CANCER PATIENTS

Shafina Nadiawati Abdul¹, Nurul Syakima Ab Mutalib¹, Ismail Sagap³, Isa Mohamed Rose⁴, Rahman Jamal¹, Raja Affendi Raja Ali^{1,5}, Norfilza Mohd Mokhtar^{1,2}

¹UKM Medical Molecular Biology Institute, ²Department of Physiology, ³Surgery, ⁴Pathology, and ⁵Gastroenterology Unit, Faculty of Medicine, Universiti Kebangsaan Malaysia, Kuala Lumpur, Malaysia

Background

Colorectal cancer (CRC) patients with similar stage may have different clinical outcomes and this suggests that the classical staging is inaccurate to predict the progression of CRC. To address this issue, we applied the targeted sequencing of specific segment of the genome to detect the pathogenic mutations in two intermediate stages of colorectal cancer.

Objectives

To investigate mutational landscape of Dukes' B and C CRC patients and to correlate with their survival.

Methodology

Targeted sequencing using Ion Ampliseq Comprehensive Cancer Panel (contains 409 tumour suppressor and oncogenes) was performed on genomic DNA of Dukes' B and C CRC patients. Clinical parameters including demographic data were recorded.

Results

A total of 19 patients (Dukes' B=10; mean age 63.2 years, Dukes' C=9; mean age 60.2 years) were studied. Majorities (84%) of cases were distal CRCs and all patients underwent surgery, 20% of Dukes' B and 100% of Dukes' C were received adjuvant chemotherapy and 20% of patients also received radiotherapy. One out of 19 patients (Dukes' B) died due to septicaemia and the remainder survive more than five years. The most frequently altered genes found were APC (63.2%), TP53 (57.9%), SYNE1 (36.8%) and KRAS (26.3%). Seventeen genes have mutation with prevalence $\geq 2\%$ and 14 of these found in both Dukes' B and C. Three additional genes namely DPYD, KDR and PRKDC found exclusively in Dukes' B. Based on the identified genomic alterations, the clinical parameters include CEA level pre and post surgery, ($p=0.4119$), ethnicity of patients ($p=0.3667$) and stages of CRC ($p=0.4706$) were not statistically significant.

Conclusion

APC remains the most significantly altered gene in the intermediate stage of CRC patients. Based on the identified genomic mutations involving APC, TP53, SYNE1 and KRAS, clinical parameters such as ethnicity, stage of CRC and pre and post surgery of CEA levels are not correlated significantly with the survival of CRC patients.

AN ASSESSMENT OF QUALITY OF LIFE IN RELATION TO THE DISEASE ACTIVITY INDEX AMONG PATIENTS WITH IBD AT UKM MEDICAL CENTRE

S Mahalinggam¹, W Z A W Abdullah¹, S Palaniappan¹, Shamsul A S², R Abdul Rani¹,
C S Ngiu¹, Norfilza Mohd Mokhtar³, R A Raja Ali^{1, 3}

¹Gastroenterology Unit, Universiti Kebangsaan Malaysia Medical Centre, Kuala Lumpur, Malaysia

²Department of Health and Statistics, Universiti Kebangsaan Malaysia Medical Centre, Kuala Lumpur, Malaysia

³UKM Medical Biology Institute, Universiti Kebangsaan Malaysia Medical Centre, Kuala Lumpur, Malaysia

Objective

Chronic diseases like inflammatory bowel disease (IBD) have an impact on the quality of life of individuals. Thus, the assessment of quality of life has become an important outcome measure in treatment studies. Our aim is to assess quality of life in relation to disease activity index among our IBD patients.

Methodology

A cross sectional study of IBD patients was performed for 4 months at our Gastroenterology unit. WHO-QOL BREF questionnaire was used to assess quality of life. Harvey-Bradshaw Index (HBI) and Lichtiger's Index were used for disease activity index in Crohn's disease (CD) and ulcerative colitis (UC) respectively.

Results

A total of 81 IBD patients [29CD, 52UC] were recruited. The median quality of life (QoL) score in the UC group was significantly higher as compared to the CD group. QoL in the remission group was better than in the group with active disease with a median score of 69 in all domains [physical health, psychological health, social relationship, and environmental health].

Discussion

Overall QoL is reduced among active IBD patients as compared to remission. UC patients shown to have better QoL. This is affected by disease behaviour of CD and younger patients in CD group thus affecting more in social relationship and psychological aspect.

Conclusion

Inflammatory bowel disease impairs patients' QoL and the impairment is very much dependant on the status of disease activity. Therefore it is crucial to induce and sustain remission in an IBD patient and QoL assessment should be implemented in the overall care of an IBD patient.

CLINICO-PATHOLOGICAL CHARACTERISTICS OF PATIENTS WHO WERE POSITIVE FOR M2-PK TEST IN THEIR STOOL, FOCUSED LOOK INTO UKM COHORT

Hajhamad M¹, Raja Affendi Raja Ali², Zairul Azwan¹, Nur Afdzillah Rahman¹, F J Ruhi¹, Sagap I¹

¹Colorectal Surgery Unit, Department of Surgery, Universiti Kebangsaan Malaysia Medical Centre, Kuala Lumpur, Malaysia

²Gastroenterology Unit, Department of Medicine, Universiti Kebangsaan Malaysia Medical Centre, Kuala Lumpur, Malaysia

Introduction

Colorectal cancer (CRC) is one of the most common cancers worldwide. Different screening programs have been developed and are offered in various countries worldwide. Detection of M2 Pyruvate Kinase enzyme (M2-PK) in patient stool is an evolving promising methods in this field. Many studies showed high sensitivity of the test, but, specificity still the issue of concern.

Objectives

To identify which patient might be false positive for M2-PK and what are the possible underlying conditions that can lead to false positive results.

Methods

A cross sectional diagnostic study was carried out at UKM medical center. Patients who, suspected or request to be screened for CRC underwent stool M2-PK testing followed by colonoscopic examination and histopathological and radiological evaluation carried on whenever applicable. Patients' demographics and clinical characteristics were obtained from patients records. Particular focus was given to those whose M2-PK test was positive, giving detailed description for their clinicopathological characteristics.

Results

Total of seventy seven patients, 36 males (46.8%) and 41 females (53.2%), were recruited in the study. Sixty seven (87%) have had negative M2-PK test, ten(13%) were positive. Of those, 5 patients (6.5%) have CRC, true positive, the other five (6.5%), false positive, they either have had a normal colonoscopy (n=1), chronic active colitis (n=2), benign ulcer (n=1) and tubular adenoma (n=1) patient. The overall sensitivity and specificity were 100% and 92.9% respectively, while positive predictive value was 50% and negative predictive value was 100%.

Conclusions

M2-PK stool test is of high sensitivity (100%) value, specificity of the test was affected, in most cases, by chronic active inflammatory process (Colitis or ulceration) which, itself, leads to high proliferation of affected cells and consequently predispose for malignancy. Further studies with larger sample size are required to further evaluate factors that may lead to false positive results.

CASE REPORT: SUCCESSFUL CONSERVATIVE MANAGEMENT OF PANCREATICO-COLONIC FISTULA FOLLOWING VIDEOSCOPIC ASSISTED RETROPERITONEAL DEBRIDEMENT OF INFECTED PANCREATIC NECROSIS

Hajhamad M¹, Reynu R, Kosai N R, Mustafa M T, Othman H²

¹Minimally Invasive, Upper GI and Bariatric Surgery Unit, Department of Surgery, Department of Medicine, Universiti Kebangsaan Malaysia Medical Centre, Kuala Lumpur, Malaysia

²Hepatobiliary Surgery Unit, Department of Medicine, Universiti Kebangsaan Malaysia Medical Centre, Kuala Lumpur, Malaysia

Objectives

Colonic involvement is a dreaded rare complication of acute severe pancreatitis. Seen in 3% of cases, it varies from torrential gastrointestinal hemorrhage, intestinal obstruction, septic shock, colonic perforation and pancreatocolonic fistula formation. Pancreatocolonic fistula is seen in 30% of cases and is associated with a high mortality risk. We highlight a rare case of pancreatocolonic fistula following a minimally invasive debridement of infected pancreatic necrosis.

Materials & Methods

A 40-year-old man presented to the emergency department and was diagnosed with acute severe pancreatitis. CT scan revealed grade E pancreatitis. Percutaneous drainage followed by VARD was performed. Post procedure, feculent material was noted in the drainage catheter. A diagnosis of pancreatocolonic fistula was made and confirmed by fistulogram.

Results

Conservative management with TPN and octreotide was adopted for 6 weeks. CT scan with oral, rectal and intravenous contrast done at the end of 6 weeks confirmed closure of the fistulous tract. The drain was removed and patient discharged home. A repeat CT 6 months later was unremarkable. Patient has been well since.

Conclusion

Pancreatocolonic fistula has been attributed to splenic vein thrombosis, external pressure by pancreatic pseudocyst, enzymatic digestion of the colonic wall and post necrosectomy. CT with rectal enema, fistulogram, and ERCP can be used to confirm diagnosis. ERCP is superior and doubles as a diagnostic and therapeutic tool. Lower incidence of pancreatocolonic fistula is seen with minimally invasive procedures compared to open necrosectomy. Only few successful cases of conservative management of pancreatocolonic fistula have been reported, making our case an important learning point to those who are just embarking on their surgical career.

IMMUNOTHERAPY IN HEPATIC SARCOIDOSIS - A CLINICAL CHALLENGE

Z Q Wong¹, Mahadeva S²

¹University Kebangsaan Malaysia Medical Centre, Kuala Lumpur, Malaysia

²University Malaya Medical Centre, Kuala Lumpur, Malaysia

Introduction

Hepatic sarcoidosis represents the hepatic component of a multisystem inflammatory disease of unknown aetiology characterized by the presence of non caseating granulomas in the organ of involvement. Systemic corticosteroids is the mainstay of treatment, but it is not always successful. We report 4 cases with variable responses to immunotherapy.

Results

All four patients were Indian females with a median age of 56.5 years. The main clinical features were fatigue, loss of weight and abdominal pain. Liver function tests featured a cholestatic picture at presentation. All patients had biopsy proven hepatic granulomas and 2/4 patients had more than one site (Lung / Lymph node) involvement. All patients received high-dose (60mg) systemic corticosteroids as first line therapy. However, only one patient responded completely to corticosteroids. The remaining 3 patients were steroid refractory or intolerant of side-effects. Immuno-suppressive agents like Methotrexate and Azathioprine were used as steroid sparing agents, but only 2/3 patients showed clinical evidence of sustained resolution or improvement. The 4th patient who was refractory to Azathioprine was commenced on Infliximab as salvage therapy and appeared to respond well. Side effects were not uncommon in our patients: cushingoid features, and adrenal suppression from high-dose corticosteroid therapy; myelosuppression with Azathioprine and recurrent infections with Infliximab.

Conclusion

Treatment of hepatic sarcoidosis remains a clinical challenge. More potent immuno-suppression may be effective in cases which are steroid-refractory.

THE CHANGING EPIDEMIOLOGY OF HEPATITIS C PATIENTS IN THE SARAWAK GENERAL HOSPITAL

V S L Kok¹, F W de Rozario¹, S Y Wong¹, S Y Soon²

¹Sarawak General Hospital, Kuching, Sarawak, Malaysia

²Kuching Specialist Hospital, KPJ, Kuching, Sarawak, Malaysia

Objective

We aim to compare the characteristics of Hepatitis C patients in the Sarawak General Hospital(SGH)

Method

A retrospective data collection of patients with Hepatitis C were obtained from the Medical Clinic from January to December 2014 and from 1995 to 2005.

Results

There were a total of 51(1995-2005) and 38 (2014) patients included in the study. Majority of the patients are male [34(89.5%) males & 4(10.5%) females in 2014 vs 39 (76%) males & 12 (24%) females in 1995-2005]. The mean age at diagnosis was 31.6 in 2014 vs 36.5 in 1995-2005.

The ethnic distribution in 2014 was 30(78.9%) Malay, 2(5.3%) Chinese, 1(2.6%) Bidayuh and 5(13.2%) Iban. The ethnic distribution in 1995-2005 was 19(37.2%) Malay, 21(41.2%) Chinese, 5 (9.8%) Bidayuh, 4(7.8%) Iban 1 (2%) Indian, and 1 (2%) Kayan.

The main source of referrals remained the blood bank: 15(39.47%) in 2014 vs 15 (29.4%) in 1995-2005. There were 5 (13.16%) patients presenting as acute Hepatitis C 2014 but none before. Other departmental referrals included 6(15.8%) in 2014 vs 20(39.3%) from 1995-2005. There were 2(3.9%) vs 11 (28.95%) referrals from the poliklinik and 2(3.9%) vs 1 (2.63%) from the district hospitals from 1995-2005 and 2014 respectively.

Risk factors were identified in 29(56.9%)[1995-2005] and 30(78.9%)[2014] patients. In 2014, 17(44.7%) patients contracted hepatitis C from intravenous drug users compared to 5(9.8%) patients 1995-2005. There were 6(15.8%) patients who acquired hepatitis C through sexual contact in 2014 and none before. There were 4(10.5%) versus 1(2%) incidence via tattoo in 2014 and 1995-2005 respectively. Patients with multiple risk factors accounted for 3(7.9%) in 2014 and 6(11.8%) in 1995-2005. The main mode of transmission 1995-2005 included blood transfusion (9;17.6%) and haemodialysis (8;15.7%); none in 2014.

Discussion

There was a significant change in the epidemiology of Hepatitis C in the two periods studied.

CASE REPORT: AN UNCOMMON CAUSE OF CHRONIC ABDOMINAL PAIN

Jasminder Kaur, Mandeep Singh, Raman Muthukaruppan, Jayaram Menon

Queen Elizabeth Hospital, Sabah, Malaysia

Introduction

Idiopathic recurrent acute pancreatitis is defined as two or more attacks of well documented acute pancreatitis of unclear cause despite an exhaustive work-up. Sphincter of Oddi dysfunction (SOD) has been associated with idiopathic recurrent acute pancreatitis

Case

We report the case of a 54 year old lady who had fifteen admissions for mild acute pancreatitis from 2004. During each presentation, she had typical pancreatic type pain with amylase levels >1000. She was extensively investigated for the cause. There was no history of alcohol consumption or traditional medication use. Her lipid profile and calcium levels were normal. The initial hepatobiliary ultrasound was normal. She had a laparoscopic cholecystectomy in 2007. CT abdomen and MRCP revealed no abnormality or features of autoimmune pancreatitis. She had an endoscopic ultrasound that showed a small filling defect with acoustic shadowing in the distal CBD suggestive of microlithiasis. She subsequently underwent ERCP with biliary sphincterotomy. There were no filling defects on cholangiogram. After sphincterotomy she continued having similar episodes of pancreatitis. She could not afford to send IgG4 levels or screening for hereditary causes of recurrent pancreatitis. She fulfilled the criteria for pancreatic SOD type 2 and had a pancreatic duct sphincterotomy. Since then, she has had no further admissions of acute pancreatitis.

Discussion

Pancreatic SOD can be classified into three groups. The goal of treating patients with symptomatic SOD is to eliminate pain and/or recurrent pancreatitis by improving the impaired flow of biliary and pancreatic secretions into the duodenum. This can be accomplished by pharmacologic, endoscopic, and surgical approaches. Endoscopic pancreatic sphincterotomy may benefit patients with pancreatitis thought to be due to SOD. In patients with recurrent pancreatitis, endoscopic sphincterotomy can result in complete and long-lasting resolution of symptoms in 64 percent.

CASE REPORT: RECURRENT ACUTE PANCREATITIS IN A YOUNG LADY

Jasminder Kaur, Mandeep Singh, Raman Muthukaruppan, Jayaram Menon

Queen Elizabeth Hospital, Sabah, Malaysia

Introduction

Pancreas divisum is a congenital anomaly that has been associated with recurrent acute pancreatitis. Fewer than 5 percent of patients develop pancreatic symptoms. Acute pancreatitis associated with pancreas divisum tends to be mild.

Case

We report a case of a 34 year old lady with three admissions for mild acute pancreatitis. She had no history of alcohol consumption or traditional medication use. During each episode, her liver enzymes were normal. Her lipid profile and calcium levels were normal. An ultrasound of the hepatobiliary system revealed no gallstone disease. She subsequently had an MRCP done. The MRCP revealed variation in the pancreatic duct suggestive of pancreatic divisum. There were two pancreatic ducts identified. The inferiorly located ventral pancreatic duct was seen communicating with the common bile duct at the major papilla. The dorsal pancreatic duct was identified with connection to the minor papilla. There was no connection between both these ducts. She underwent minor duct sphincterotomy.

Discussion

There are several different types of pancreas divisum - classic pancreas divisum, incomplete pancreas divisum and a reverse divisum. In a group of patients, the minor papilla orifice is so small that excessively high intrapancreatic dorsal ductal pressure occurs during active secretion, which results in inadequate drainage, ductal distension, pain, and, in some cases, pancreatitis. Treatment of minor papilla narrowing in pancreas divisum has traditionally been approached surgically. However, similar results are being obtained in experienced centres with endoscopic approaches. Studies have shown that approximately 75 percent of patients with pancreas divisum who have idiopathic acute recurrent pancreatitis are improved after endoscopic therapy.

Conclusion

In conclusion, pancreas divisum should be considered in the differentials of a patient with recurrent idiopathic pancreatitis. Endoscopic therapy should be considered in the management of pancreas divisum as it has a similar response as to surgical approach.

A RETROSPECTIVE ANALYSIS OF COLORECTAL CANCERS DIAGNOSED IN QUEEN ELIZABETH HOSPITAL

Jasminder Kaur, Mandeep Singh, Raman Muthukaruppan, Jayaram Menon

Queen Elizabeth Hospital, Sabah, Malaysia

Background

In Malaysia, colorectal cancer (CRC) is the most common cancer in males and second most common in females.

Objectives

To evaluate the demographics, clinical, endoscopic and histological details of patients who were diagnosed with CRC.

Methodology

Data collection was done from July 2007-Dec 2014 based on the registry in Queen Elizabeth Hospital, Sabah.

Results

Data from a total of 371 cases of CRC were analyzed during this period. The incidence of CRC was higher in males 213 cases (57%) than in females 158 cases (43%). The highest numbers of cases were reported in the 50-59 year age group (27%). 23% of cases were diagnosed below the age of 50. Mean age of diagnosis was 58 years. The ethnic distribution is as follows: Chinese 131(35%), Others 105 (28%), Bajau 48 (13%), Dusun 37 (10%) and Kadazan 21 (5%). The main presentation was altered bowel habit (60%), abdominal pain (60%), blood in stool (50%), weight loss (50%), intestinal obstruction (20%), and anemia (15%). The most frequent site was rectum 97 (26%), sigmoid colon 84 (23%) and rectosigmoid 48 (13%). The histology types in 93% were adenocarcinoma of usual type, 3.6% were mucinous type, 2.6% were signet ring carcinomas and there was 1 case of neuroendocrine carcinoma. Total of 79% of patients were operated on and another 21% did not undergo operative management due to old age, metastatic disease and patient refusal.

Conclusion

Our data shows greater incidence of CRC in the Chinese population in keeping with the National Cancer statistics. The mean age at diagnosis was 58 years and justifies commencing screening at the age of 50 years. A significant number of patients were diagnosed below the age of 50. Those who fulfill the Bethesda Criteria should have microsatellite-instability testing so that family screening can be performed at an earlier age.

A REVIEW OF HEPATOBILIARY TUBERCULOSIS – A SABAH EXPERIENCE

*Jasminder Kaur, James Emanuelle, Nerentheran Loganathan, Mandeep Singh,
Raman Muthukaruppan, Jayaram Menon*

Queen Elizabeth Hospital, Sabah, Malaysia

Background

Hepatobiliary tuberculosis (HTB) is a distinct entity in which hepatic and biliary involvement overwhelmingly dominates the clinical picture. HTB accounts for less than 1% of all tuberculous infections.

Objectives

To evaluate the clinical presentation, diagnosis, endoscopy finding of patients diagnosed with HTB.

Methodology

A retrospective analysis was carried out on all HTB cases diagnosed under the gastroenterology clinic in Queen Elizabeth Hospital from January 2008-May 2015.

Results

A total of 11 patients with hepatobiliary tuberculosis were identified. Five had isolated organ involvement [hepatic (n=1) and biliary (n=4)] and six had multiorgan involvement. Common clinical presentations were jaundice (73%), hepatomegaly (55%), abdominal pain (55%), weight loss (45%) and fever (36%). The mean time from symptom onset to presentation was 200 days (range 7-710). Alkaline phosphatase and transaminases were abnormal in 91% of patients. 82% had abnormal albumin-globulin ratio. Diagnosis was made by presence of caseating granuloma in biopsy of liver (n=4), bile duct (n=1), colonic ulcer (n=1) and peritoneal nodule (n=1). Two were diagnosed based on presence of caseous necrotic material on EUS-FNA of celiac node and pancreatic lesion respectively. One patient's bile culture was positive for tuberculosis and another had active pulmonary tuberculosis. ERCP findings in the seven jaundiced patients with biliary involvement revealed CHD stricture in five, CBD stricture in three and beaded IHD in two. Two patients no longer required restenting after completion of treatment. Another two still require long term stenting. Another three patients are undergoing treatment, one of which no longer requires restenting. Malignancy was initially suspected in 55%. Treatment duration ranged from 12-18 months. Two patients developed secondary biliary cirrhosis and portal vein thrombosis respectively.

Conclusion

HTB is often difficult to diagnose. There should be a strong index of suspicion in tuberculosis endemic areas as delay in diagnosis can result in significant morbidity.

EFFECTS OF TYPE D PERSONALITY ON FOLLOW-UP DURATION AND ADHERENCE TO MEDICATIONS AMONG GERD PATIENTS

Kosholah B, Kugan V, Shrinivan G, Jovi C J H, Mahadevan D

Department of General Surgery, Tuanku Ja'afar Hospital, Seremban, Negeri Sembilan, Malaysia

Objective

Personality type has been proven to affect adherence to medications and compliance to medical advises. Personality Type D or 'distressed' is characterized by two components which are negative affectivity and social inhibition. GERD (gastroesophageal reflux disease) is a chronic and relapsing disease.

Aim

To compare follow up duration and adherence to medication between personality Type D and Non Personality Type D among patients with GERD.

Methodology

This is retrospective cohort study of 63 patients with GERD from Tuanku Ja'afar Hospital, Seremban conducted from July 2014 until June 2015. Patients with relapsing GERD with medication. Social demographic data and outcome measures such as adherence to medication, duration of hospital follow up and personality type were collected. SPSS V7 was used to analyze data. Mean, standard deviation, Odds ratio and Chi Square were used.

Result

Total 65 patients, 44% had Type D Personality and the remaining was non Type D. Ratio male to female is 1:1.5. The mean age was 51.13 15.4. No significant differences between the baseline comparisons of the two groups. Study demonstrated that Type D personality had significantly higher follow up duration in hospital ($p < 0.05$) (OR, 3.05; 95% CI 1.08-8.56). Relative risk: 5.9; Patients with Type D personality have 6 times greater risk of being non compliant.

Discussion and Conclusion

This study showed that majority patients who have follow up duration of more than 5 years are those with Type D personality. These patients require longer follow up compared to non Type D personality patients because of poor adherence and frequent disease relapses. In future we can choose appropriate treatment for patients with GERD which may include both pharmacological and psychological intervention.

SCREENING OF FUNCTIONAL CONSTIPATION AMONG STUDENTS IN UNIVERSITI PUTRA MALAYSIA, SERDANG

Ying-Jye L¹, Rosita J¹, J Y Chieng², P Yap², Rajesh P²

¹Department of Nutrition and Dietetics, Faculty of Medicine and Health Sciences, Universiti Putra Malaysia, Selangor, Malaysia

²Department of Medicine, Faculty of Medicine and Health Sciences, Universiti Putra Malaysia, Selangor, Malaysia

Background and objective

Constipation is one of the commonest functional bowel disorders. The prevalence in the general population is 12% to 19% and in Asia it is 15% to 23% for women and about 11% for men, with an increasing trend in the last decade. The etiology is poorly understood and management has dismal outcome. Thus, the objective of this screening is to explore the prevalence of functional constipation among students in Universiti Putra Malaysia with the intention to introduce treatment in the future.

Methodology

The screening activity for functional constipation was conducted based on Rome III diagnostic criteria with the aid of Bristol Stool Chart to characterize stool consistency. A cross sectional questionnaire-based survey was done among students from the foundation studies, undergraduates and postgraduates in UPM from November 2014 to April 2015.

Results

About 1603 subjects (96.6%) responded to the questionnaire, aged 18 to 52 years old. From a total of 1558 subjects included in the study, after excluding 45 subjects, the prevalence rate for functional constipation was 17.01%. Of 265 subjects with functional constipation, 81.5% were females. 65.2% of the subjects were reported to have less than three defecations in a week. Incomplete evacuation (91.7%) and anorectal obstruction/blockage (90.9%) were found as the most common symptoms experienced among the constipated subjects. Majority of the subjects reported the need to strain during defecations (50.9%), hard/lumpy stools (48.7%) and use manual maneuvers (45.3%). Stool consistency was checked using Bristol Stool Chart and Type 3 was the commonest reported (35.8%).

Conclusion

The prevalence of functional constipation is 17.01% in UPM students with mainly Type 3 stool consistency. Further interventional studies are essential to look at outcome of treatment with regards to symptoms in this group.

PREVALENCE OF HELICOBACTER PYLORI INFECTIONS AMONG PATIENTS REFERRED FOR ENDOSCOPY AT HOSPITAL SULTAN ABDUL HALIM

Kirubakaran Ranita¹, Ooi Ching Yee¹, Su Kim Peng², Izhar Nur Amira²

Hospital Sultan Abdul Halim, Sungai Petani, Malaysia

Introduction

Helicobacter pylori (*H. pylori*) is a gram-negative bacterium which is considered a contributory agent of peptic ulcer disease, gastric lymphoma, and gastric carcinoma.

Objectives

To determine the prevalence of *H. pylori* infection according to age, gender, ethnicity, and endoscopic finding. To study the association between smoking and alcohol consumption with *H. pylori* infection.

Methodology

A retrospective observational study on 582 consecutive patients referred for endoscopy with *H. pylori* tested was conducted in Hospital Sultan Abdul Halim from 1st of January 2013 till 31st of December 2013. Data was analyzed using Pearson's chi square, Fisher's exact test and Binary logistic regression with Statistical Package for Social Science (SPSS) version 16.

Results

Out of the 582 patients, 74 (12.7%) were positive for *H. pylori* infection. Among those with *H. pylori* infection, 42 (56.8%) were female. Infection was highest in the age group of 51 to 60 years old, 25 (33.8%) with the mean age of 52.9 ± 14.9 years. From the endoscopic finding, gastritis and duodenitis, 32 (43.0%) had the highest *H. pylori* positive cases. *H. pylori* infection was commonly found among Indians (36.3%;41/113) followed by Chinese (17.6%,18/102) and Malays (4.1%;15/367), $p < 0.05$. There is no significant association between smoking and alcohol consumption with *H. pylori* infection, $p > 0.05$.

Conclusion

The increased risk of *H. pylori* infection in Indians might be due to ethnic genetic predisposition or unusual socio-cultural practices which may be responsible for the transmission of the infection. Therefore, further studies are warranted.

PROFILE AND OUTCOME OF VARICEAL BLEEDING PATIENTS REFERRED FOR ENDOSCOPY AT HOSPITAL SULTAN ABDUL HALIM

Kirubakaran Ranita, Ooi Ching Yee, Su Kim Peng, Syah Rizal Irwan

Hospital Sultan Abdul Halim, Sungai Petani, Kedah, Malaysia

Introduction

Variceal bleeding is a major complication of portal hypertension and is a leading cause of death in patients with cirrhosis.

Objectives

To determine the prevalence of variceal bleeding and to identify the etiology of cirrhosis. To assess the intervention during endoscopy and to determine the outcome of intervention.

Methodology

A retrospective observational study on 95 consecutive patients referred for endoscopy with the first episode of variceal bleeding was conducted in Hospital Sultan Abdul Halim from 1st of January 2013 till 31st of December 2013. Data was analyzed using Microsoft Excel 2007.

Results

Majority of the patients were male, 63(66.3%) and Malay, 63(66.3%). The mean age was 59.0 \pm 10.8 years. Variceal bleeding was highest in the age group of 51 to 60 years old, 36(37.9%). From the endoscopic finding, 69(72.6%) were of oesophageal variceal bleeding. Among those with liver cirrhosis, 23(33.3%) were due to hepatitis C. 39(41.1%) underwent endoscopic variceal ligation (EVL), 4(4.2%) received sclerotherapy and 25(26.3%) received intravenous (IV) terlipressin. In-hospital mortality and re-bleeding were 2(2.1%) and 10(10.5%) respectively. The median (IQR) hospital stay was 1 (1,2) day.

Conclusion

Relatively low in-hospital mortality and re-bleeding rates most probably due to the smaller proportion of patients with severe liver dysfunction and management which adhered to clinical practice guideline.

AN INCIDENTAL FINDING OF AN EXTRALUMINAL DUODENAL DIVERTICULUM

Thevaraajan Jayaraman, Rafiz Abdul Rani, Mohd Ilham Abdul Hafidz, Annamalai Chandramouli

Gastroenterology Unit, Department of Internal Medicine, Faculty of Medicine, Universiti Teknologi MARA (UiTM), Selangor, Malaysia

Case

A 68 year old Malay gentleman attended the Gastroenterology Clinic in UiTM Selayang Campus complaining of worsening heartburn and bloatedness. He denies any nausea and vomiting. He reports no significant weight loss and no change in bowel habit. He is a chronic smoker of 10 cigs/day for the last 50 years and does not consume alcohol. He is known to suffer from dyspepsia in the past and had a good clinical response to a trial of proton pump inhibitor. Currently he is not taking any regular medications. He is also known to suffer from right knee osteoarthritis, eczema and a benign bladder tumour. Clinical examination was unremarkable.

Patient subsequently underwent an upper GI endoscopy and was found to have oesophagitis, pangastritis and an incidental finding of a large extraluminal diverticulum in the first part of the duodenum. CLO test was negative.

Discussion

The duodenum is the second most common site of diverticula after the colon. Diagnosis is often incidental. Extraluminal duodenal diverticula are noted in 5% of upper GI x-rays and seen in 20% to 30% of ERCP studies. They are thought to be acquired and appear more commonly with increased age. Usually they are located in the second part of the duodenum close to the ampulla of Vater. Duodenal diverticula rarely cause clinical problems such as perforation, diverticulitis and bleeding.

Conclusion

There has been no known reports of diverticula occurring in the first part of the duodenum as we found in this patient. The symptoms present in this patient is unlikely to be related to his duodenal diverticulum and can be explained by the presence of oesophagitis and gastritis found on upper GI endoscopy.

References

1. Sakthivel S, Kannaiyan K, and Thiagarajan S, 2013, Prevalence of Duodenal Diverticulum in South Indians: A Cadaveric Study, *ISRN Anatomy*, vol. 2013, Article ID 767403, 5 pages, available from <http://dx.doi.org/10.5402/2013/767403>
2. Feldman M, Friedman L.S. and Brandt L.J., 2015, *Sleisenger and Fordtrans Gastrointestinal and Liver Disease*, Tenth Edition, Elsevier, USA

INCIDENCE OF UPPER GASTRO-INTESTINAL CANCER IN HOSPITAL TUANKU JA'AFAR, SEREMBAN FROM 2008-2014. A POPULATION BASED TREND ANALYSIS

Mohanraj T¹, A Vijaya Shankar¹, Azrina A B¹, Kandasami P², Mahadevan D Tata¹

¹Hospital Tuanku Ja'afar, Seremban, Negeri Sembilan, Malaysia

²International Medical University, Seremban, Negeri Sembilan, Malaysia

Background

Cancer originating from esophagus, gastro-esophageal junction (COJ) and stomach poses a major health problem worldwide. Upper gastro intestinal cancers (Upper GI ca) generally present late and it is one of the common causes for cancer related death worldwide.

Aim

To describe the recent trend in incidence of Upper GI cancers in local population.

Method

This is a cross sectional retrospective study of Upper GI cancer data from January 2008 to December 2014 in Hospital Tuanku Ja'afar, Seremban. All patients' records of histologically confirmed upper GI cancers during the study period were reviewed. Data collected includes demographics, cancer diagnosis and treatment.

Results

There were total 199 cancer cases with 124 males and 75 females reported. Mean age for Upper GI ca is 62.8, gastric ca 62.6, esophageal ca 65.0, COJ ca 58.9. Cancer incidence among Chinese population was higher with 41% (81), followed by Malay 34.4% (68), Indian 23.7% (48) and others 1% (2). Gastric ca incidence was 59.6% (118), esophageal ca 22.7% (45), COJ ca 14.1% (29) and others was 3.6% (7). The incidence of Upper GI cancers declined over 7 years with COJ and esophageal cancers are increasing in trend. By population gastric ca is more prevalent in Chinese while COJ and esophageal ca are more prevalent in Malays and Indians. Among Chinese, Esophageal ca incidence is declining while gastric ca is increasing. 54% (107) patients diagnosed at late stage III & IV (gastric, esophagus) while 5% (10) diagnosed early (stage I and II) for all Upper GI cancers. For COJ cancers, most patients diagnosed at Siewert III 82.4% (14 patients), Siewert II 11.8%, (2 patients), Siewert I 6% (1 patient).

Conclusion

Upper GI cancers especially COJ tumor are rapidly increasing. An increased focus on prevention and early diagnosis programmes are required to improve outcome of these cancers.

THE PATTERNS OF BLEEDING PEPTIC ULCER DISEASE AND METHODS OF ENDOSCOPIC HAEMOSTASIS: A SINGLE CENTRE EXPERIENCE

S Rosemi, A B Norasiah, J W Aina, M Norhashimah

Gastroenterology Unit, Department of Medicine, Hospital Raja Perempuan Zainab II, Kota Bharu, Kelantan, Malaysia

Objective

To study the pattern of PUD bleeding and types of endoscopic haemostasis in various type of PUD bleeding and its location.

Methodology

The record of cases confirmed as bleeding PUD from January 2014 till June 2015 were retrospectively evaluated. Several parameters were evaluated which include age, sex, type of PUD causing bleeding and its Forrest's classification, location of ulcer and modality of endoscopic haemostasis either monotherapy or dual therapy or triple therapy using adrenaline injection or / and heater probe / argon plasma / endoclip / endoclot spray

Results

403 cases of Bleeding PUD were evaluated, predominantly were male (53.5%) with mean age of 64.7 year old (range: 22 to 96). The site of ulcer bleeding were 53.3% (215) from Duodenal Ulcer and 46.7 % (188) from Gastric Ulcer with Forrest classification as follows, F1 is 71 (17.6%), F2 was 111 (27.5%) and F3 was 221 (54.9%), severe lesion (F1 and F2) predominantly in DU (62.3%). Total of haemostasis procedure performed were 132, where 49 (37.1%) were monotherapy, 63 (47.7%) were dual therapy and 20 (15.2%) were triple therapy. In term of location of haemostasis procedures, monotherapy were 30 (33%) in DU and 29 (47.5%) in GU, dual therapy were 43 (47.3%) in DU and 30 (49.2%) in GU and Triple therapy were 18 (19.8%) in DU and 2 (3.3%) in GU .

Discussion

Bleeding PUD were more common in elderly male and the primary ulcer bleeding were more common in Duodenal Ulcer than Gastric Ulcer (53.3% vs 46.7%). Severe ulcer lesion (F1 and F2) less common than mild ulcer lesion (F3) (45.1% vs 54.9%) detected in bleeding PUD. Most common modality of haemostasis procedure was dual therapy followed by monotherapy and triple therapy respectively, while DU lesion were commonly need endoscopic haemostasis compared to GU lesions

Conclusion

Bleeding PUD is more commonly due to duodenal ulcer compared to gastric ulcer, while F3 ulcer lesion is more common compared to F1 and F2 ulcer lesion. Majority of endoscopic haemostasis achieved by dual therapy and DU bleeding most commonly required haemostasis procedure.

FIRST CASE REPORT OF BEEF TAENIASIS FROM SABAH, MALAYSIA

James Emmanuel¹, Nagaraj Sriram¹, Mandeep Singh¹, Raman Muthukaruppan¹, Jayaram Menon¹, Tock H Chua²

¹Department of Medicine, Hospital Queen Elizabeth, Kota Kinabalu, Sabah, Malaysia

²Department of Pathobiology & Medical Diagnostics, Faculty of Medicine and Health Sciences, Universiti Malaysia Sabah, Kota Kinabalu, Sabah, Malaysia

Introduction

Taeniasis is a parasitic disease of the human intestinal tract caused by the adult stage of the closely related tapeworms *Taenia solium*, *Taenia saginata*, and *Taenia saginata asiatica*. It is endemic in Southeast Asia and is acquired by taking improperly cooked beef or pork.

Case report

We present a case of a 56 years old Dusun gentleman, a veterinarian assistant, hailing from Kota Belud, who presented in June 2014 with complaints of passing loose stools which contained worms for the past 6 years. This was associated with abdominal discomfort, loss of appetite and weight. He had been given a total of 13 courses of Albendazole between June 2008 to December 2013 from various GPs which provided only a brief respite in his symptoms each time. He was subsequently referred to our unit in June 2014 and after obtaining a detailed history uncovered an interesting facet of his dietary history which included consumption of raw beef, the timing of which coincided with the onset of his symptoms. Serum biochemical and hematological parameters were within the normal range.

OGDS and colonoscopy performed revealed pangastritis and a adenomatous rectal polyp respectively. There were no worms noted endoscopically. Stool specimens were examined under stereo-microscope and then subjected to molecular identification. PCR-based molecular diagnosis identified the causative organism as *Taenia Saginata*. Patient was treated accordingly with Praziquantel and has been asymptomatic since.

Discussion

T. Saginata is the largest of species in the genus *Taenia*. Differentiation of the species of *Taenia*, is notoriously difficult because of their close morphological resemblance, and their eggs are more or less identical which underlines the importance of PCR based molecular diagnosis.

Conclusion

It is conceivable that this patient may not be the only case in Sabah as symptoms of taeniasis are usually mild or nonexistent,

CHRONIC HEPATITIS C TREATMENT - LABUAN HOSPITAL EXPERIENCE

Raman Muthukaruppan¹, Vinoth Rajan², Hema Yamini², Saw Y T²

¹Hospital Queen Elizabeth, Kota Kinabalu, Sabah, Malaysia

²Hospital Labuan, Wilayah Persekutuan Labuan, Malaysia

Objective(s)

To ascertain the disease burden and efficacy of standard of care (SOC) antiviral therapy in patients with chronic hepatitis C in Hospital Labuan.

Methodology

Retrospective, observational study of all suitable chronic hepatitis C patients treated with pegylated interferon injection and oral ribavirin from January 2011 to June 2015. Sustained Virological Response (SVR) was defined as undetected HCV RNA at 24 weeks after treatment.

Results

A total of 43 patients seen between 2011 and 2015. 10 (23.2%) patients completed treatment. Nine (90%) were males and 1(10%) was female. The mean age was 38.4 years. Major risk factors being sexual promiscuity (5 patients) and intravenous drug abuse (3 patients). Unknown in 4 patients. Five patients (50%) had concomitant illnesses (hypertension, dyslipidaemia and/or diabetes mellitus).

Nine patients (90%) had genotype 3a. One patient (10%) had genotype 1a. Ultrasound pre-treatment revealed four with fatty liver and one with liver cirrhosis. Five had normal findings. Mean pre-treatment viral load was 5.46 logs IU/ml. All patients were treated with Peg-Intron and ribavirin. Treatment complication only encountered in one patient who had anaemia and neutropenia, requiring dose adjustment and erythropoietin injection. SVR was achieved in 7(70%) patients. 2(20%) had relapse and 1(10%) was a non-responder. Among 2 patients who relapsed, one had genotype 1a and the other genotype 3a. The genotype 3a patient had concomitant diabetes mellitus which could be the reason for relapse.

Conclusion

Our study reveals genotype 3a as the predominant genotype and male sex being the majority. Response to SOC treatment was excellent with majority of patients (70%) achieving SVR. Almost all except for one had no complications or adverse effects to treatment.

Discussion

The number of patients being treated here is small, mainly due to the treatment cost and lack of awareness.

CASE REPORT: SUPERIOR MESENTERIC ARTERY SYNDROME IN A PATIENT WITH COLORECTAL CANCER

James Emmanuel¹, Lily Lim Hooi Min², Nagaraj Sriram¹, Mandeep Singh¹, Raman Muthukaruppan¹, Wan NajwaZaini Bt Wan Mohamed², Jayaram Menon¹

¹Department of Medicine, Hospital Queen Elizabeth, Kota Kinabalu, Sabah, Malaysia

²Department of Radiology, Hospital Queen Elizabeth, Kota Kinabalu, Sabah, Malaysia

Introduction

Superior mesenteric artery (SMA) syndrome first described in 1861 by Rokitansky is a rare acquired disorder in which acute angulation of SMA causes compression of the 3rd part of the duodenum between the SMA and the aorta, leading to obstruction. The most characteristic symptoms are post-prandial epigastric fullness with pain, eructation, and bilious vomiting.

Case report

An 80 year old asthenic lady diagnosed with metastatic adenocarcinoma of the descending colon in June 2014 underwent colonic stenting and subsequently completed 10 cycles of palliative chemotherapy with FOLFOX and De Gramont in December 2014. She underwent a Laparoscopic-assisted Left Hemicolectomy in June 2015 following a presentation for acute intestinal obstruction and was discharged well. A week later she presented with worsening epigastric pain and severe post prandial vomiting. A CT (Computed Tomography) abdomen done excluded an anastomotic leak. Barium studies revealed a dilated stomach and 2nd part of the duodenum with extrinsic compression at the 3rd part of duodenum. Attempted endoscopic introduction of a nasojejunal tube failed due to complete blockage of the duodenum. She underwent a retrocolic duodenojejunostomy, side to side anastomosis. During post-operative follow up, patient remained symptom free.

Discussion

SMA syndrome (Wilkie's syndrome) is a vascular compression of the 3rd portion of the duodenum. Conservative initial treatment is recommended in all patients with SMA syndrome; this includes adequate nutrition, nasogastric decompression and posture therapy. Surgical treatment is recommended in cases of clinical treatment failure.

Conclusion

SMA syndrome is a rare entity that does not enable proper food intake. Contrast study of the duodenum can provide a number of signs compatible with its diagnosis. In some patients, CT abdomen is required to confirm the diagnosis. Surgical treatment of SMA syndrome is recommended only when conservative treatment has failed as illustrated in this case.

A GASTRIC BEZOAR IN BILLROTH II STOMACH: A CASE REPORT ON SUCCESSFUL ENDOSCOPIC REMOVAL VIA REPEATED FRAGMENTATION AND DISSOLUTION TECHNIQUES NEGATING THE NEED FOR SURGICAL INTERVENTION

J Y Chieng¹, S H Ho², K L Goh²

¹Faculty of Medicine and Health Science, Putra University of Malaysia, Selangor, Malaysia

²Department of Medicine, University of Malaya, Kuala Lumpur, Malaysia

Case Report

A 76-year-old gentleman presented with iron deficiency anaemia with positive fecal occult blood test. The patient had a history of perforated duodenal ulcer six years ago, with laparotomy repair (Billroth II) performed. A large gastric bezoar (about 8X6cm², of hard consistency) with a prepyloric ulcer (Forrest class III, with clean base) was found during the initial oesophagoduodenoscopy (OGDS). Rapid urease test was negative. He presented with melena during the subsequent follow up (OGDS showed a bleeding prepyloric ulcer of Forrest class Ib).

We have successfully removed the gastric bezoar with dissolution therapy using Coca-cola initially (injection of coke-cola into the bezoar, followed by drinking 325ml coca-cola twice daily), followed by four attempts of OGDS with endoscopic fragmentation using hot polypectomy snare.

Result

Histopathology reported as degenerated vegetable matter, acellular debris mixed with scattered fungal and bacterial colonies, which was compatible with bezoar.

Follow up OGDS showed complete clearance of the bezoar.

Discussion

A bezoar is an indigestible mass of material found in the gastrointestinal tract. Gastric bezoars usually result from ingestion of indigestible material in patients with impairment in the gastric motility or digestion or in those with delaying gastric emptying. A wide variety of therapeutic options have been reported.

This patient's history of gastric surgery was a factor for formation of gastric bezoar.

The gastric bezoar had been successfully softened by ingestion of Coca-cola, and to be segmented into smaller pieces using hot polypectomy snare, followed by removal with Roth net. The sodium bicarbonate in Coca-cola has a mucolytic effect, and the carbon dioxide bubbles may penetrate into the bezoar, leading to digestion of the fibers.

Conclusion

Coca-cola ingestion should be considered as initial treatment as it is non-invasive, and it enables further successful endoscopic fragmentation.

CASE REPORT: A CASE OF VON HIPPEL LINDAU PRESENTING WITH PANCREATIC CYST

James Emmanuel, Nagaraj Sriram, Mandeep Singh, Raman Muthukaruppan, Jayaram Menon

Medical Department, Hospital Queen Elizabeth, Kota Kinabalu, Sabah, Malaysia

Introduction

Von Hippel Lindau (VHL) disease is a rare autosomal dominant disorder with a prevalence estimated to be between 1:35,000- 1:40,000. It is most commonly familial (80%) however 20% of patients will present with a de novo mutation. The pancreatic lesions associated with VHL include pancreatic cysts, serous microcystic adenomas and adenocarcinomas.

Case report

A 46 year old lady with no prior comorbidities presents with history of chronic epigastric pain for 2 years. She otherwise reported no constitutional symptoms or change in bowel or bladder habits. Vital signs and systemic examination was unremarkable. Bidirectional endoscopy done in a private centre due to her persistent symptomatology was normal. CT abdomen and pelvis undertaken showed multiple pancreatic cysts and intramural uterine cervix cysts. Endoscopic Ultrasound (EUS) evaluation revealed a pancreas studded with simple cysts and serous cystadenoma. VHL was suspected based on these findings. Fine-needle aspiration for evaluation of the cyst was consistent with non-mucinous cyst.

As part of the VHL workup a CT brain was done which noted a right parasagittal enhancing lesion in keeping with a meningioma. Ophthalmological assessment excluded the presence of retinal lesions. 24 hour urine catecholamine results were not representative of the presence of pheochromocytoma.

The preliminary genetic tests confirmed VHL and she is undergoing further genetic analysis.

Discussion

Pancreatic lesions, including cysts, may precede any other manifestation of von Hippel-Lindau disease by several years, and recognition permits earlier diagnosis in patients being screened for von Hippel-Lindau disease.

Conclusion

VHL is multisystemic disorder which requires correct diagnosis, monitoring and management. The mainstay of follow up is by radiological imaging modalities like USG, CT and MRI. For all patients who present with multiple pancreatic cysts, testing for von Hippel-Lindau syndrome should be included as part of the diagnostic workup.

CASE REPORT : EUS GUIDED PSEUDOCYST DRAINAGE : A CASE OF PANCREATIC PSEUDOCYST WITH UNDERLYING SMALL CELL NEUROENDOCRINE CARCINOMA OF THE UTERINE CERVIX

James Emmanuel, Nagaraj Sriram, Mandeep Singh, Raman Muthukaruppan, Jayaram Menon

Medical Department, Hospital Queen Elizabeth, Kota Kinabalu, Sabah, Malaysia

Introduction

Pancreatic pseudocyst is defined as a collection of pancreatic juice enclosed by a wall of fibrous or granulation tissue which is not lined by epithelium

Case report

A 45 year old lady with a background history of neuroendocrine carcinoma of the cervix (Stage 4 B) completed 6 cycles of chemotherapy - Cisplatin & Etoposide between July to November 2014. Further cycles of single agent Cisplatin was given following the repeat CT which showed favourable response. She was referred to our Unit in March 2015 due to worsening abdominal pain for 2 months. A CT abdomen carried out revealed a multilobular cystic lesion in the region of lesser sac suggestive of pancreatic pseudocyst with radiological features of pancreatitis. An EUS guided pseudocyst drainage was performed using a 10 F pigtail catheter which was again reinserted 2 weeks later after the former had dislodged. Cyst fluid analysis showed very high levels of amylase (> 5000) and low levels of CEA (< 2). Cyst fluid cultures were negative. A MRCP performed after the drainage, confirmed pseudocyst communication with the pancreatic duct. Incidentally a distal CBD stricture was noted. This was followed up with an ERCP and plastic stent insertion into the CBD and PD respectively.

Discussion

EUS guided pseudocyst drainage can be performed using the transmural placement of a stent. The success and complications of EUS guided pseudocyst drainage are comparable with or better than the results reported from surgical interventions. Demonstrable communication of the pseudocyst with the PD will require additional ERCP to be performed. Biliary stenting may be necessary especially if there is CBD compression.

Conclusion

- EUS guided pseudocyst drainage is a safe procedure particularly if local expertise are available. Stent migration is a known complication.
- Pancreatitis is a rare side effect of cisplatin.

UPPER GASTROINTESTINAL ENDOSCOPIC EVALUATION OF IRON DEFICIENCY ANEMIA IN CHRONIC KIDNEY DISEASE PATIENTS

C K Lee¹, Saravanan A¹, E S Tan¹, L T Gew¹, Jaideep S¹, Y Y Ngau²

¹Gastroenterology Unit, Medical Department, Hospital Kuala Lumpur, Kuala Lumpur, Malaysia

²Medical Department, Hospital Kuala Lumpur, Kuala Lumpur, Malaysia

Objectives

To review the endoscopic diagnosis of patients with chronic kidney disease (CKD) with eGFR < 60ml/min referred for evaluation of iron deficiency anemia (IDA) and risk factors associated with the diseases identified.

Methodology

A retrospective study which include the patients who had oesophagogastroduodenoscopy (OGDS) from January/2014 - June/2015 using database from Malaysia Gastro-Intestinal Registry (MGIR).

Results

A total of 69-patients were recruited which comprised of 48-males and 2-females (37-Malays, 20-Chinese, 10-Indians and 2-Burmese). Majority (61-patients) are aged >50. The endoscopic diagnosis are mainly gastroduodenitis (42=patients/61%) followed by normal finding (7-patients/10.1%), gastric ulcer (7-patients/10.1%), erosive gastritis (6-patients/8.7%), esophageal ulcer (2-patients/2.9%), duodenal ulcer (2-patients/2.9%) and 1-patient each (1.4% each) with portal hypertensive gastropathy, gastric antral vascular ectasia and hiatus hernia. Only 15 patients used antiplatelet (67% gastroduodenitis, 20% no lesions and 13% gastric ulcers). No patients used regular NSAIDs, steroid, anticoagulation or traditional-medicines. Only 5 out of all the 69 patients (7%) were tested positive with rapid urease test and all had gastroduodenitis.

Discussion

Uremia itself rather than Helicobacter Pylori infection or medications causes the upper gastrointestinal disease. However, majority of the gastroduodenitis are mild with only 8 and 3 patients were labelled as moderate and severe respectively. All the esophageal, gastric and duodenal ulcers are small Forrest III (<1cm) except 1 patient with Forrest IIc antral ulcer. All erosive esophagitis were graded as Los Angeles Grade A and B. These findings alone might not explain the iron deficiency.

Conclusion

OGDS alone is inadequate for chronic gastrointestinal blood loss assessment of IDA in CKD hence colonoscopy is needed to complete the evaluation.

COLONOSCOPY EVALUATION OF CHRONIC DIARRHOEA IN DIABETIC PATIENTS

C K Lee¹, Saravanan A¹, E S Tan¹, L T Gew¹, Jaideep S¹, Y Y Ngau²

¹Gastroenterology Unit, Medical Department, Hospital Kuala Lumpur, Kuala Lumpur, Malaysia

²Medical Department, Hospital Kuala Lumpur, Kuala Lumpur, Malaysia

Objectives

Audit of Colonoscopy for Diabetis-Mellitus(DM) patients referred for evaluation chronic diarrhea (>3 soft-stools daily for >1month).

Methodology: A retrospective study which include the DM patients who had colonoscopy for assessment of chronic diarrhea from July/2010 - June/2015 using database from Malaysia Gastro-Intestinal Registry (MGIR).

Results

After excluding those with constitutional symptoms and colorectal carcinoma risk factors, a total of 80 patients were recruited which comprised of 39 males and 41 females (28-Malays, 14-Chinese, 37-Indians and 1-Burmese). 67 patients (84%) are aged >50. The significant endoscopic diagnosis are diverticulosis (10-patients/12.5%), carcinoma (8-patients/10%), colitis (8-patients/10%), ulcers (4-patients/5%) and ileitis (2-patients/2.5%) and the rest are normal (24-patients/30%) followed by polyps (14-patients/17.5%) and hemorrhoid (10-patients/12.5%).

Discussion

Diabetic intestinal enteropathy related to autonomic dysfunction has reported incidence up to 30% which concurs with our study which was reported as normal colonoscopy. However age is an important risk factor as 7 out of 8 patients with cancer are aged more than 50 with both Chinese and Indian preponderance (3-patients each- total 75%). One patient diagnosed with ulcerative colitis and other patients with colitis were likely infective in nature. The limitation of this study are the duration and control of DM and findings of upper gastrointestinal endoscopy (for investigation of possible malabsorption) not analyzed which may be the cause of diarrhea.

Conclusion

Colonoscopy is an important investigational stool for chronic diarrhea in diabetic patients as more than 40% patients have significant findings. However, non invasive investigations such as small intestinal bacterial overgrowth (SIBO) test and malabsorption assessment including upper gastrointestinal endoscopy should be done.

AUDIT OF UGIE ON ASYMPTOMATIC PATIENT GOING FOR RENAL TRANSPLANT

L T Gew¹, Navanithan R¹, C K Lee¹, E S Tan¹, Jaideep S¹, Saravanan A¹, Y Y Ngau²

¹Gastroenterology Unit, Medical Department, Hospital Kuala Lumpur, Kuala Lumpur, Malaysia

²Medical Department, Hospital Kuala Lumpur, Kuala Lumpur, Malaysia

Objective

Routine upper Gastro Intestinal endoscopy (UGIE) is performed for asymptomatic patient with end stage kidney disease (ESRD) before transplant.¹ This is done to detect structural abnormality in upper GI and provide treatment to prevent it worsening at post-transplant period; especially when immunosuppression (including steroid) is used. Our study aim to investigate the UGIE findings in such population.

Methodology

We studied retrospectively patients with ESRD who were undergoing routine UGIE from year 2009-2015 before renal transplantation. The rapid urease test was done to screen for Helicobacter pylori infection. Demographic and endoscopy data were collected via Malaysia Gastrointestinal Registry (MGIR).

Results

We studied 94 patients (52 male, 42 female, mean age 39.9 years old). Endoscopy was normal in 19 patients (20%). Significant endoscopic findings were esophagitis (38.3%), gastric or duodenal erosion (30.9%), gastric ulcer (8.5%) and duodenal ulcer (1.1%). The rapid urease test was positive in 6.4% of patients. Other endoscopy findings include erythema gastritis or duodenitis.

Discussion

The pre-renal transplant UGIE surveillance is effective in detecting a total of 58.5% of structural abnormality. Some patients have more than 1 significant structural lesions.

Conclusion

UGIE is an important workout for ESRF patient going in for Renal transplant as in this audit we detected significant structural abnormality in this patient even though they did not have any upper GI symptoms.

OUTCOME OF PATIENTS WITH DERANGED LIVER FUNCTION TEST WITH OR WITHOUT LOSS OF SYNTHETIC FUNCTION OF LIVER IN SEVERE DENGUE

L T Gew¹, C C Tan¹, C K Lee¹, E S Tan¹, Jaideep S¹, Saravanan A¹, Y Y Ngau²

¹Gastroenterology Unit, Medical Department, Hospital Kuala Lumpur, Kuala Lumpur, Malaysia

²Medical Department, Hospital Kuala Lumpur, Kuala Lumpur, Malaysia

Objective

To study the pattern of alteration of liver biochemical test in serologically confirmed patients who diagnosed with severe dengue (WHO criteria, 2009)

Methodology

We retrospectively analyzed 33 patients admitted to ICU Hospital Kuala Lumpur in March-April 2015 for severe dengue. 2 patients were excluded due to evidence of co-bacterial infection. Results: Patient age 13-68 years old with 17 males and 16 females. The peak Aspartate Transaminase (AST & Alanine Transaminase (ALT) occurred at day 6 of fever. In 32% of the cases, peak of transaminases happened before defervescence. In the remainder of patients, it happened at 0-3 days after the defervescence. Abnormality of AST, ALT, alkaline phosphatase, total bilirubin level and prolonged prothrombin time (PT) were observed in 100%, 99.9%, 19.4%, 0.1%, 16% of the patients respectively. Median of the peak ALT and AST was 125 U/L and 233 U/L. 90% of the patient has AST/ALT > 1. 29% of the patient has ALT > 300 U/L and 10% of the patient has ALT > 1000 U/L.

Discussion

Pattern transaminases derangement concurs with previous dengue liver biochemical studies. Severe hepatitis (defined as ALT > 300 U/L, 10 times upper normal limit) occurred in 29% of this cohort. Out of this, 2 patients (6.5%) passed away and their ALT were 2771 U/L and 3475 U/L, respectively. 16% of the patients presented with prolonged PT but there were no further workup to confirmed liver failure or DIVC.

Conclusion

Liver involvement is common in severe dengue. The significant rise of ALT with impaired synthetic function of liver may associated with poor outcome.

EFFECT OF FIBRIN GLUE IN PREVENTION OF DELAYED BLEEDING POST GASTRIC ENDOSCOPIC SUBMUCOSAL DISSECTION

E S Tan¹, Feng Liu², Hua Wang³

¹Gastroenterology Unit, Medical Department, Hospital Kuala Lumpur, Kuala Lumpur, Malaysia

²Changhai Hospital, Shanghai, China

Objective

To evaluate the effectiveness of fibrin-glue(FG) in preventing delayed bleeding post ESD .

Methods

423 patients who underwent gastric ESD from 2011-2014. A total of 26 patients were excluded: 5 patients were excluded due to intra-operative complications another 21 patients were excluded because endoscopic submucosal tunneling method . The remaining 397 patients were enrolled in the study. ESD were performed by 2 experts in Changhai Hospital. Each has the experience of performing > 100 cases of ESD/year for the past 5 years. Patients were divided into 2 groups:

1. FG group patients with post operative use of porcine derive fibrin glue;
2. Non FG Group: Group of patients without the use of porcine derived fibrin glue.

Post operative events of each group were collected and compared.

Results

The mean age of patients was 55.5 + 12.2 years. A total of 403 lesions were resected from 397 patients. In all 397 patients, ESD was successfully completed. There was no statistical significant difference in the gender and age between FG Group and Non FG Group. Neither is there any statistical significance in location of lesions, numbers of coagrasper and haemoclips used between the two groups.

In the FG group, there was significantly more cancerous lesions resected($P=0.017$) and the lesions are significantly larger in size (diameter >40mm) ($P<0.001$) as compared to the non FG group.

Our current study showed that the used to fibrin glue significantly reduced the risk of delayed bleeding ($P=0.03$). Size of lesions ($P=0.002$) and cancerous lesions ($P=0.027$) also showed statistical significance. Meanwhile, age, gender, location of lesion, use of coagrasper or hemoclips have no statistical significance in relation to delayed bleeding.

Conclusions

The use of fibrin glue post gastric ESD is effective in preventing delayed bleeding. Size of lesions is a risk factor for delayed bleeding.

CHRONIC HEPATITIS C GENOTYPE 1 TREATMENT WITH BOCEPREVIR/PEGINTERFERON ALFA-2A/RIBAVIRIN: LOCAL SABAH EXPERIENCE

Sriram Nagaraj, Siew Phung Tan, James Emmanuel, Mandeep Singh, Raman Muthukaruppan, Jayaram Menon

Department of Medicine, Hospital Queen Elizabeth, Kota Kinabalu, Sabah, Malaysia

Objective

To determine the success rate and tolerability of Boceprevir/Peginterferon Alfa-2a/Ribavirin in the treatment of Chronic Hepatitis C genotype 1 (One).

Methodology

Retrospective study of case notes and clinical information of patients with Chronic Hepatitis C Genotype 1 treated with Boceprevir/Peginterferon Alfa-2a/Ribavirin in Queen Elizabeth Hospital, Sabah.

Results

Nine patients were treated with Boceprevir/Peginterferon Alfa-2a/ Ribavirin. Eight out of these nine patients (88.9%) were successfully treated and achieved Sustained virological response (SVR) while one patient did not complete his treatment due to side effects. Eight patients were treatment naïve patients while 1 patient was a non-responder who has been previously treated with peginterferon Alfa-2a/Ribavirin for 48 weeks. Out of the nine patients who were treated, three (33.3%) patients had Anemia during treatment and two out of them had to be given s/c Erythropoeitin. None of them received blood transfusion. Two patients (22.2%) had depression and one of them had to stop treatment prematurely. Two patients had significant weight loss with mean of 12.5 kg.

Discussion and Conclusion

Majority of our patients with Chronic Hepatitis C Genotype 1 who underwent treatment with Boceprevir/Peginterferon Alfa-2a/Ribavirin achieved remarkable success in terms of achieving SVR. Only a few of these patients had significant adverse effects namely anemia and depression which were overcome rather easily. Limiting factor of this study is the number of patients and a larger study is needed to confirm our findings.

CASE REPORT: DISTAL ESOPHAGEAL STRICTURE – A RARE PRESENTATION OF A COMMON DISEASE - TUBERCULOSIS

Sriram Nagaraj, James Emmanuel, Mandeep Singh, Raman Muthukaruppan, Jayaram Menon

Medical Department, Hospital Queen Elizabeth, Kota Kinabalu, Sabah, Malaysia

Background

Extra pulmonary Tuberculosis is becoming more prevalent in our country. Most common sites being lymphatic, genitourinary, bone and joint, central nervous system, abdominal, and pericardium. Extra pulmonary tuberculosis is far more challenging to clinicians in terms of diagnosis and management. This maybe because it's less common and therefore less familiar to most clinicians. In addition, extra pulmonary tuberculosis involves relatively inaccessible sites, and often the combination of small numbers of bacilli in inaccessible sites makes bacteriologic confirmation of a diagnosis more difficult, and invasive procedures are frequently necessary to establish a firm diagnosis. Here we present a rare case of Extra pulmonary Tuberculosis involving an extra luminal mass at lower esophageal junction presenting with dysphagia.

Case

A 29-year old lady presented with dysphagia more to solids for three months associated with weight loss of 5 kg over this period. Physical examination was unremarkable. OGDS revealed food and stricture over the lower end of esophagus with normal appearing mucosa. Barium swallow showed a long segment stricture at distal esophagus. CT Thorax revealed an extra luminal, multiseptated, solid-cystic mass measuring 3.4 cm x 3.1 cm x 5.4 cm at the gastro-esophageal junction causing narrowing of the distal esophageal lumen. No significant upper abdominal or mediastinal lymphadenopathy. Endoscopic Ultrasound (EUS) and Fine needle Aspiration (FNA) of the mass was done. Cytology showed epithelioid granuloma with giant cells and caseous necrosis. Ziehl-Neelson stain was negative for acid fast bacilli. She was subsequently started on Anti Tubercular Treatment and a polyflex esophageal stent was inserted to relieve her symptoms.

Conclusion

This is a rare presentation of extrapulmonary Tuberculosis in the esophagus which was successfully diagnosed by EUS-FNA.

CASE REPORT : PRIMARY DUODENAL ASPERGILLOSIS – CASE REPORT IN IMMUNOCOMPETENT ADULT

Sriram Nagaraj, James Emmanuel, Mandeep Singh, Raman Muthukaruppan, Jayaram Menon

Medical Department, Hospital Queen Elizabeth, Kota Kinabalu, Sabah, Malaysia

Background

Primary Duodenal Aspergillosis in an immunocompetent adult is extremely rare. Many cases of pulmonary, cutaneous, cerebral, and paranasal sinus aspergillosis in immunocompetent patient were defined in literature but primary duodenal aspergillosis has only been reported in 2 case series. Here we present an immunocompetent case with duodenal aspergillosis.

Case

A 28-year old gentleman with no known medical illness presented with worsening epigastric pain for four months associated with abdominal distension, post-prandial vomiting and early satiety. There was loss of weight of 12 kgs and loss of appetite for the past two months. On presentation, OesophagoGastroDuodenoScopy was done showing large duodenal ulcer with necrotic base measuring around 10 x 8 cm with no evidence of gastric outlet obstruction. Helicobacter pylori was positive. Multiple biopsies taken revealed septated fungal hyphae which are pleomorphic and branching. No dysplasia and malignant changes seen. Biopsy of the ulcer was also sent for fungal culture which grew Aspergillus niger. Initial CT scan of abdomen showed heterogeneously enhancing exophytic mass at pylorus. No evidence of fungal infection noted in thorax. Clinically no evidence of paranasal sinus involvement. He is a non-diabetic, tested negative for HIV infection and no other evidence of systemic illness. He was treated with IV Amphotericin B for 6 weeks and repeat OGDS then showed much smaller ulcer measuring 4 x 2 cm.

Conclusion

Primary Gastrointestinal Aspergillosis is very rare. The exact etiology or predisposing factors in our patient is unknown.

CASE REPORT: BILIARY ASCARIASIS – CAUSE OF RECURRENT ABDOMINAL PAIN DIAGNOSED WITH ENDOSCOPIC ULTRASOUND

Sriram Nagaraj, James Emmanuel, Mandeep Singh, Raman Muthukaruppan, Jayaram Menon

Medical Department, Hospital Queen Elizabeth, Kota Kinabalu, Sabah, Malaysia

Background

Biliary Ascariasis is a major concern in the tropical and subtropical countries with significant morbidity and mortality. In Malaysia, it has been described in the past but due to our nation's growth and development, incidence of biliary ascariasis has reduced. In Sabah rural population, ascariasis is still prevalent and worms in the biliary system may produce features of recurrent pyogenic cholangitis, acute pancreatitis and liver abscess. Ascariasis lumbricoides normally lives in the upper small bowel without causing symptoms. We present a case of 41 year old lady who presented with recurrent abdominal pain which turned out to be biliary ascariasis.

Case

41 year old lady presented to emergency Department multiple times for recurrent abdominal pain over the past 2 weeks. She was initially treated as dyspepsia and discharged. Initial blood tests showed elevated alkaline phosphatase, elevated GGT, mild transaminitis, with normal bilirubin levels. Initial Ultrasound was suggestive of chelystitis. Due to persistent symptoms and elevated alkaline phosphatase, we performed an Endoscopic Ultrasound (EUS) which showed filling defects in the Intrahepatic ducts as well as common bile duct. The filling defects appear tubular with acoustic shadowing. Diagnosis of Biliary ascariasis was made and an Endoscopic Retrograde Cholangio Pancreatography (ERCP) was done and 4 worms were removed which led to resolution of her symptoms.

Conclusion

Biliary Ascariasis is still prevalent in our country especially in rural population. High clinical suspicion is needed to diagnose and treat such conditions.

A RETROSPECTIVE, OBSERVATIONAL STUDY ON EFFECT OF PROTON PUMP INHIBITORS ON THE OUTCOME OF PEPTIC ULCER BLEEDING: COMPARISON BETWEEN IV ESOMEPRAZOLE AND IV PANTOPRAZOLE

Sriram Nagaraj¹, Hui Ling Tay¹, Peter Tok², James Emmanuel¹, Mandeep Singh¹, Raman Muthukaruppan¹, Jayaram Menon¹

¹Medical Department, Hospital Queen Elizabeth, Kota Kinabalu, Sabah, Malaysia

²Clinical Research Centre, Hospital Queen Elizabeth, Kota Kinabalu, Sabah, Malaysia

Background

Peptic ulcer bleeding is a common hospitalization cause worldwide, with incidences of 19.4-57.0 cases per 100,000 individuals for ulcer hemorrhage and 3.8-14 cases per 100,000 individuals for perforation, respectively. In our centre, both Esomeprazole and Pantoprazole is being used in the management of Peptic Ulcer Bleeding.

Objective

This study aims to compare the effects of these two proton pump inhibitors (PPI): IV esomeprazole and IV pantoprazole, in management of patients with peptic ulcer bleeding. The outcome of interest include re-bleeding rate, within 30 days and In-hospital mortality.

Methodology

This is a retrospective study designed to compare the effects of these two PPI: IV esomeprazole and IV pantoprazole, in management of patients with peptic ulcer bleeding, with respect to the outcomes of interest outlined in the previous section. Secondary data will be retrieved from medical case notes and reports of patients managed by gastroenterology unit in Hospital Queen Elizabeth, and extracted into a clinical report form (CRF)

Results

These are the preliminary results of this on-going study. To date, 104 subjects (35 IV Esomeprazole and 69 IV Pantoprazole) have been analyzed. Both groups were matched for demographics, prognostic factors, risk scores (Rockall, Blatchford and AIMS65) and therapeutic modality utilized to achieve hemostasis. Majority of subjects were male (85.6%) and 39 subjects (37.5%) presented with hypovolumic shock. Using Fisher's exact test, the proportion of re-bleeding between IV Esomeprazole and IV Pantoprazole are not significantly different ($p=0.267$). Therefore there is no significant association between the type of PPI used and re-bleeding. There was no cases which required surgery within 30 days. Similarly, no deaths were reported among the cases within 30 days.

Conclusion

In this preliminary results, the proportion of re-bleeding between IV Esomeprazole and IV Pantoprazole are not significantly different.

CHYLOUS ASCITES AS A RARE MANIFESTATION OF CONGESTIVE CARDIAC FAILURE

Ganesh Kasinathan, Mohd Shafiq Rahman, Sirajudeen Rowther

Department of Internal Medicine, Hospital Segamat, Johor, Malaysia

Background

Chylous ascites is an uncommon type of ascites which may be associated with liver diseases, tuberculosis or malignancy. However, in a minority of cases, it is due to heart failure.

Case Presentation/Results

This case report describes a 59 year old Malay gentleman who presented with multiple episodes of abdominal distension for the past six months associated with exertional dyspnoea, orthopnoea, paroxysmal nocturnal dyspnoea and bilateral leg swelling. He denied any fever, night sweats, anorexia or loss of weight. He did not exhibit any altered bowel habit or vomiting. Physical examination revealed a non tender, distended abdomen with an everted umbilicus. His legs were swollen bilaterally till the knees. Jugular venous pulsations were raised. Lungs revealed bibasal crepitations. Abdominal paracentesis revealed milky turbid appearing peritoneal fluid. Laboratory studies showed a transudative chylous ascites. Tuberculous workout and viral hepatitis screening were negative. His transthoracic echocardiogram revealed global hypokinesia with a left ventricular ejection fraction of 30%. Contrast enhanced CT scan of the thorax, abdomen and pelvis showed features consistent of liver cirrhosis with portal hypertension most probably attributable to the severe heart failure. There was no evidence to suggest malignancy. He was started on anti-heart failure drugs in which his ascites showed significant improvement within three months.

Conclusion

Congestive cardiac failure should be considered as one of the causes for chylous ascites.

Keywords

ascites, swelling, abdomen, chylous, turbid

GASTROINTESTINAL LUMINAL TUBERCULOSIS: 21 CASES COLLECTED IN HOSPITAL QUEEN ELIZABETH IN KOTA KINABALU, SABAH

James Emmanuel¹, Thamron Keowmani², Grace Tay Hui Ling¹, Nagaraj Sriram¹, Mandeep Singh¹, Raman Muthukaruppan¹, Jayaram Menon¹

¹Department of Medicine, Queen Elizabeth Hospital, Kota Kinabalu, Sabah, Malaysia

²Clinical Research Centre, Queen Elizabeth Hospital, Kota Kinabalu, Sabah, Malaysia

Introduction

Tuberculosis can involve any part of the gastrointestinal tract and is the sixth most frequent site of extrapulmonary involvement. It can have a varied presentation, frequently mimicking other common and rare diseases.

Objectives

To describe the clinical and diagnostic characteristics of patients diagnosed with gastrointestinal luminal tuberculosis and to reassess the endoscopic response of the gastrointestinal lesions after ATT (anti tuberculosis treatment)

Methodology

A cross-sectional study of gastrointestinal luminal tuberculosis cases that were diagnosed between January 2014 and June 2015. All data were collected from the patients' case notes.

Results

Twenty-one cases of patients with luminal tuberculosis were collected. Twelve cases (57.1%) were female. Six of the patients (28.6%) had active pulmonary tuberculosis. The three most common symptoms were weight loss (57.1%), abdominal pain (52.4%) and fever (47.6%). The three most common signs were abdominal tenderness (42.9%), abdominal distension (28.6%) and abdominal mass (28.6%). The most common site of involvement was the ileocecal valve (52.4%). The most common colonoscopy and CT findings were ulcerative lesions (66.7%) and bowel wall thickening (52.4%) respectively. Histological evidence of caseating granuloma were found in 18 cases (85.7%). Mycobacterium tuberculosis was detected by ZN stain in 3 cases (14.3%), however none were successfully cultured. Majority (81.0%) of the cases were treated by Akurit 4. Seven cases (33.3%) had treatment related complications. Follow-up colonoscopy were done in 19 cases (90.5%) all of whom demonstrated resolution of previously noted lesions.

Discussion

TB of the colon predominantly affects the the ileocaecal region due its abundance of lymphoid tissue. Colonic lesions generally resolve with anti-TB treatment, including strictures, thereby suggesting that strictures are more inflammatory rather than fibrotic in nature.

Conclusion

Gastrointestinal TB predominantly involves the ileocecal valve. Ulceration, is the prominent endoscopic finding. Macroscopic lesions noted endoscopically commonly show resolution with anti-TB treatment.

OUTCOME OF THE COLORECTAL CANCER SURVEILLANCE COLONOSCOPY

Saravanan A¹, E S Tan¹, Jaideep S¹, C K Lee¹, L T Gew¹, Y Y Ngau²

¹Gastroenterology Unit, Medical Department, Hospital Kuala Lumpur, Kuala Lumpur, Malaysia

²Medical Department, Hospital Kuala Lumpur, Kuala Lumpur, Malaysia

Objectives

Audit on the Colorectal-Cancer (CRC) surveillance-colonoscopy (CRC-SC) to obtain the incidence of CRC.

Methodology

Single center retrospective study from July 2014 till July 2015. Data on demography and colonoscopy finding were retrieved from Malaysian Gastro-Intestinal registry (MGIR).

Results

Total of 5498 colonoscopy was done during the study duration. About 282/5.13 % (Male 154/54.01% & Female 128/45.99%) colonoscopies were done for the indication of CRC-SC. The indications of CRC-SC were subtyped into High Risk Group (HRG) 97/35% and Average Risk Group (ARG) 185/65%. CRC detected in 13/5% (HRG 6 cases and ARG 7 cases). The Colonic polyp (CP) detection in the patient undergone CRC-SC was reported in 88/31% colonoscopies. About 37/42% CRC-SC had 3 or more CP. There was 15/17% CP > 6mm in size (ranging from 6mm to 25mm). The CP polyp types were 20/22.7% flat CPs, 48/55.4% sessile-CPs, 19/21.6% pedunculated with short-stalk-CPs and 3/3.4% pedunculated with long-stalk-CPs.

Discussion

CRC surveillance is a routine screening test in an asymptomatic patient age 50-year-old patient and above. They are further divided to HRG or ARG to decide the mode of screening modality which includes immune-chemical FOBT, sigmoidoscopy or colonoscopy. CRC-SC needs to be practiced to benefit our patients for early pre-cancerous lesion detections and treatment hence prevention of CRC. In this study only 5.13% colonoscopy was done for the indication of CRC-SC.

Conclusion

CRC-SC is an imperative screening procedure in prevention of CRC in our population. Patient awareness on prevention of CRC needs to be increased and mass CRC-SC practiced need to be encouraged.